

Head Trauma

For any traumatic injury that involves the head; includes multi-system trauma that involves the head

History

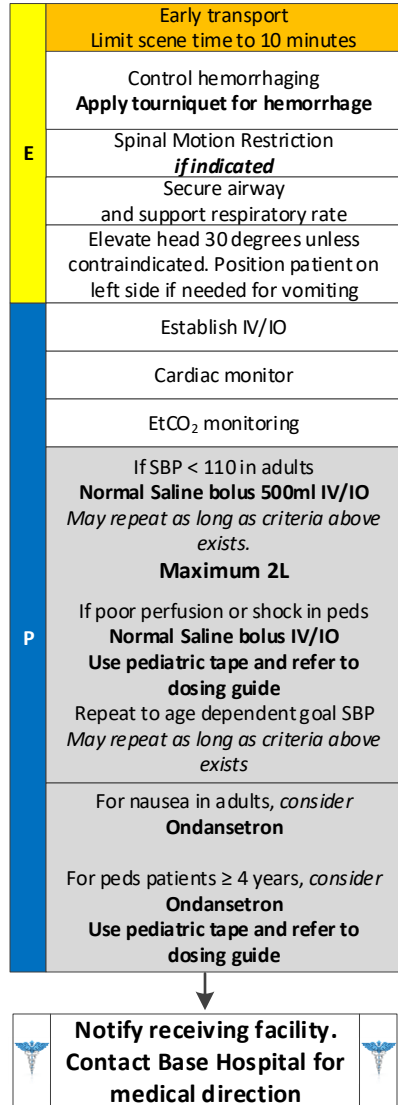
- Time of injury
- Mechanism (blunt vs. penetrating)
- Loss of consciousness
- Bleeding
- Past medical history
- Medications (anticoagulants)

Signs and Symptoms

- Evidence of trauma
- Pain, swelling, or bleeding
- AMS
- Unconscious
- Respiratory distress or failure
- Vomiting
- Seizure

Differential

- Skull fracture
- Spinal injury
- Abuse



Respiratory Arrest/Failure
if indicated

Tourniquet use should not be delayed until a patient is in shock or is clearly exsanguinating. It should be applied early and can be used safely without risk of patient injury. Do not wait; apply often and tighten if needed.

Head Trauma

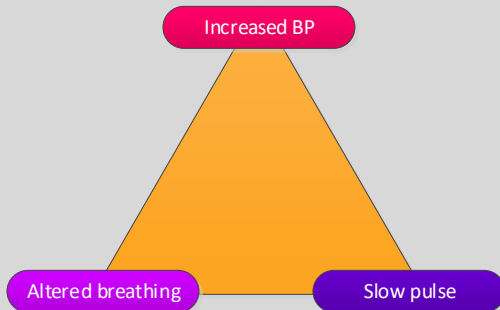
For any traumatic injury that involves the head; includes multi-system trauma that involves the head

Increased Intracranial Pressure

Changes in LOC
Impaired eye movement
↓ sensory/motor function

Infants

Bulging fontanels
Cranial suture separation
↑ head circumference
High-pitched cry



Headache
Pupillary changes
Vomiting
Changes in vital signs
 ↑ Blood pressure
 ↓ Pulse
 Changes in respiratory pattern

Pearls

- ALS procedures in the field do not significantly improve patient outcome in critical trauma patients.
- Basic airway management is preferred unless unable to effectively manage with BLS maneuvers. Utilize modified jaw thrust technique to open the airway.
- Intubation of head injury patients is best addressed at the hospital.
- Hypotension is age dependent and is not always a reliable sign. It should be interpreted in context with the patient's typical BP, if known. Shock may be present with a seemingly normal blood pressure initially.
 - Neonate: < 60mmHg or weak pulses
 - Infant: < 70mmHg or weak pulses
 - 1-10 years: < 70mmHg + (age in years x2)
 - Over 10 years: <90mmHg
 - Over 65 years: <110mmHg
- Avoid hyperventilation. Maintain an EtCO₂ of 35 or greater, which may be unreliable if the patient was subject to multisystem trauma or poor perfusion.
- In patients with a dilated pupil on one side or posturing, which indicates brainstem herniation, modest hyperventilation is appropriate. Keep EtCO₂ of 30 or greater.
- Scalp hemorrhage can be life threatening. Treat with direct pressure and pressure dressing.
- Increased intracranial pressure may cause hypertension and bradycardia.
- Hypotension usually indicates injury or shock unrelated to the head injury and should be treated aggressively.
- An important item to monitor and document is a change in the level of consciousness by repeat examination.
- Limit IV fluids unless the patient is hypotensive.
- Concussions are traumatic brain injuries involving any number of symptoms including confusion, LOC, vomiting, or headache. Any prolonged confusion or mental status abnormality which does not return to the patient's baseline within 15 minutes of injury or any documented LOC should be evaluated by a physician.
- Do not overlook the possibility of associated domestic violence or abuse.

