

Pediatric Hypothermia/Cold Injury

For environmental exposures causing hypothermia and/or frostbite injury

History

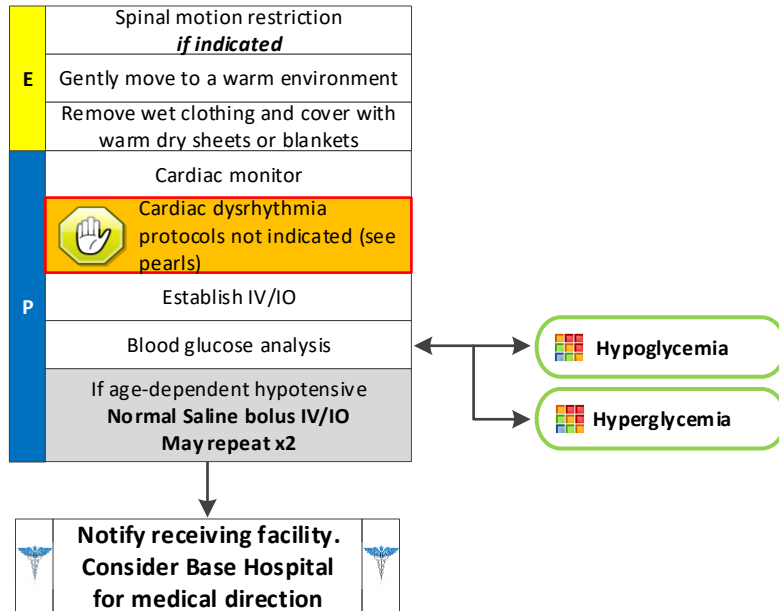
- Age
- Exposure to decreased temperatures, but may occur in normal atmospheric temperatures
- Time and length of exposure
- Drug or alcohol use
- Infection or sepsis
- Past medical history
- Medications

Signs and Symptoms

- AMS
- Cold or clammy skin
- Shivering
- Extremity pain or sensory abnormality
- Bradycardia
- Hypotension or shock

Differential

- Sepsis
- Environmental exposure
- Hypoglycemia
- CNS dysfunction
 - Stroke
 - Head injury
 - Spinal cord injury



Pearls

- Severe hypothermia may cause cardiac instability. Avoidance of excess stimuli is important in severe hypothermia as the heart is sensitive and interventions may induce arrhythmias. Necessary interventions should be done as gently as possible. If available, use warm saline.
- Check for pulselessness for 30-45 seconds to avoid unnecessary chest compressions.
- Defer ACLS medications until patient is warmed (normothermic). Patients with hypothermia may have good neurologic outcome despite prolonged resuscitation; resuscitative efforts should continue until the patient is rewarmed.
- If V-Fib or pulseless V-Tach is present, shock x1, and defer further shocks.
- Extremes of age, malnutrition, alcohol, and other drug use are contributing factors to hypothermia.
- Patients with prolonged hypoglycemia often become hypothermic; blood glucose analysis is essential.
- If a temperature is unable to be measured, treat the patient based on the suspected temperature.
- Warm packs can be placed in the armpit and groin areas. Care should be taken not to place directly on skin.

