

# End Tidal CO<sub>2</sub> (EtCO<sub>2</sub>) Monitoring

**Applies to:**

**P** Paramedic

**Clinical Indications:**

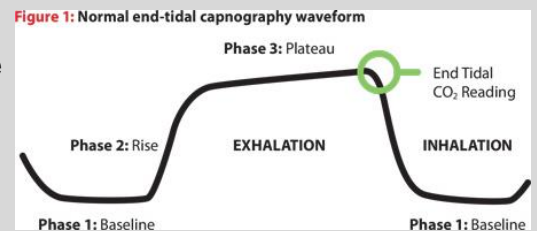
1. Capnography shall be used when available with the use of all advanced airway procedures and as required by treatment guidelines.

**Procedure:**

1. Attach capnography sensor to the monitor first to allow for room air calibration, then attach to the advanced airway or any other oxygen delivery device, including bag-valve mask and nasal cannula.
2. Note that EtCO<sub>2</sub> level and waveform changes. Values shall be documented in the ePCR.
3. The capnometer shall remain in place and be monitored throughout prehospital care and transport.
4. Any loss of EtCO<sub>2</sub> detection or waveform may indicate an airway problem and should be immediately addressed and thoroughly documented.
5. Document the procedure and results in the ePCR.

**Notes:**

1. EtCO<sub>2</sub> readings may be unreliable if the patient is in shock or has poor perfusion.
2. Normal EtCO<sub>2</sub> levels range from 30s and 40s, but this may vary based on the patient's underlying respiratory and metabolic status.
3. EtCO<sub>2</sub> levels that rise from a normal baseline to or above 50 may indicate hypoventilation is occurring.
4. Patient stimulation, use of a BVM, or use of Naloxone may be appropriate based on the situation.



Causes of Elevated EtCO <sub>2</sub>	Causes of Decreased EtCO <sub>2</sub>
<b>METABOLISM</b> Pain Hyperthermia Shivering	<b>METABOLISM</b> Hypothermia Metabolic acidosis
<b>RESPIRATORY SYSTEM</b> Respiratory insufficiency Respiratory depression COPD Analgesia/sedation	<b>RESPIRATORY SYSTEM</b> Alveolar hyperventilation Bronchospasm Mucus plugging
<b>CIRCULATORY SYSTEM</b> Increased cardiac output	<b>CIRCULATORY SYSTEM</b> Hypotension Sudden hypovolemia Cardiac arrest Pulmonary emboli
<b>MEDICATIONS</b> Bicarb administration	

<p><b>Sudden loss of waveform</b></p> <ul style="list-style-type: none"> <li>• ET tube disconnected, dislodged, kinked or obstructed</li> <li>• Loss of circulatory function</li> </ul>	<p><b>Decreasing EtCO<sub>2</sub></b></p> <ul style="list-style-type: none"> <li>• ET tube cuff leak</li> <li>• ET tube in hypopharynx</li> <li>• Partial obstruction</li> </ul>	<p><b>Bronchospasm ("Shark-fin" appearance)</b></p> <ul style="list-style-type: none"> <li>• Asthma</li> <li>• COPD</li> </ul>
<p><b>CPR Assessment</b></p> <ul style="list-style-type: none"> <li>• Attempt to maintain minimum of 10mmHg</li> </ul>	<p><b>Sudden increase in EtCO<sub>2</sub></b></p> <ul style="list-style-type: none"> <li>• Return of spontaneous circulation (ROSC)</li> </ul>	<p><b>Hypoventilation</b></p>
		<p><b>Hyperventilation</b></p>
		<p><b>Decreased EtCO<sub>2</sub></b></p> <ul style="list-style-type: none"> <li>• Apnea</li> <li>• Sedation</li> </ul>