

Wide Complex Tachycardia

History

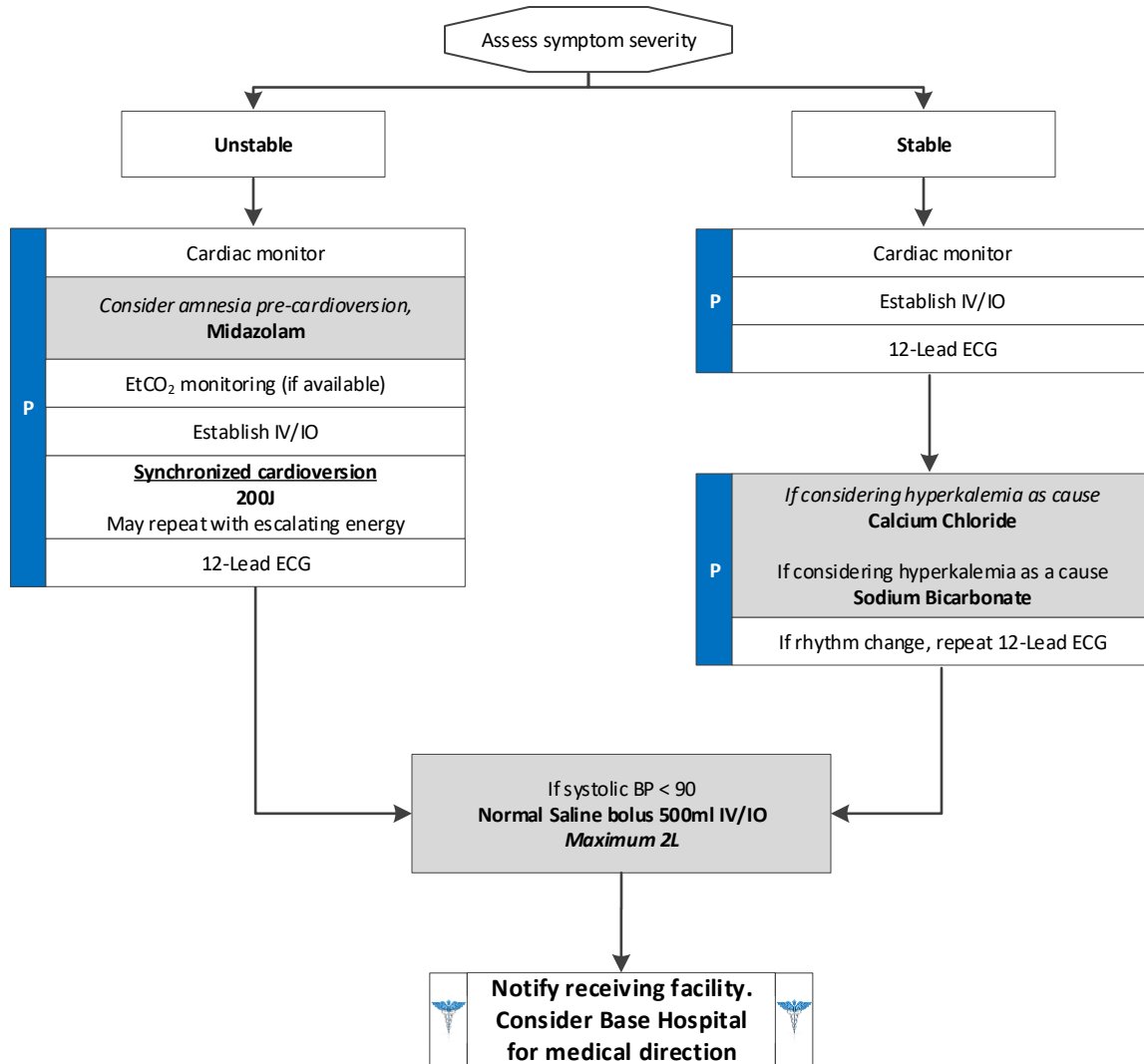
- Medications (e.g., Aminophylline, Adderall, diet pills, thyroid supplements, decongestants, and Digoxin)
- Diet (e.g., caffeine and chocolate)
- Drugs (e.g., nicotine and illegal drugs)
- Past medical history
- History of palpitations/heart racing
- Syncope/near syncope
- Renal failure
- Missed dialysis

Signs and Symptoms

- Heart rate > 150
- Systolic BP < 90
- Dizziness, chest pain, shortness of breath, altered mental status or diaphoresis
- Acute pulmonary edema
- Potential presenting rhythm:
 - Atrial/sinus tachycardia
 - Atrial fibrillation/flutter
 - Multifocal atrial tachycardia
 - Ventricular tachycardia

Differential

- Heart disease (e.g., WPW or valvular)
- Sick sinus syndrome
- Myocardial infarction
- Electrolyte imbalance
- Exertion, pain, or emotional stress
- Fever
- Hypoxia
- Hypovolemia or anemia
- Drug effect/overdose (see **History**)
- Hypothyroidism
- Pulmonary embolus



Wide Complex Tachycardia

Pearls

- Most important goal is to differentiate the type of tachycardia and if STABLE or UNSTABLE.
- If at any point the patient becomes unstable, move to the unstable arm of the algorithm.
- For ASYMPTOMATIC patients (or those with only minimal symptoms, such as palpitations) and any tachycardia with a rate of approximately 100 – 120 with a normal blood pressure, consider CLOSE OBSERVATION or fluid bolus.
- Unstable Signs/Symptoms include: Hypotension; acutely altered mental status; signs of shock/poor perfusion; chest pain with evidence of ischemia (e.g., STEMI, T-wave inversions, or depressions); and acute pulmonary edema.
- Search for underlying cause of tachycardia such as fever, sepsis, dyspnea, etc.
- Monitor for respiratory depression and hypotension associated with Midazolam.
- Activate and upload all monitor data.
- Consider trial of Adenosine to rule out SVT with aberrancy.

