

Seizure – Active

For seizure witnessed by EMS, whether treated or not

History

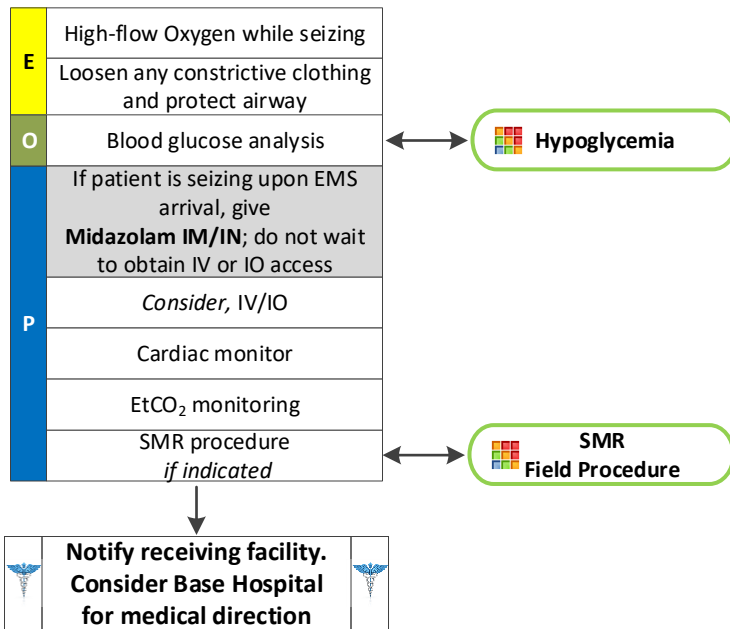
- Reported or witnessed seizure
- Previous seizure history
- Medical alert tag
- Seizure medications
- History of trauma
- History of diabetes
- History of pregnancy
- Time of seizure onset
- Document number of seizures
- Alcohol use, abuse, or abrupt cessation
- Fever

Signs and Symptoms

- Altered mental status
- Tonic/clonic movements
- Incontinence
- Seizure activity
- Evidence of trauma
- Unconscious
- Incontinence
- Tongue biting
- Blank stare
- Rhythmic facial movement

Differential

- Head trauma
- Metabolic, hepatic or renal failure
- Tumor
- Hypoxia
- Electrolyte abnormality
- Drugs or medication non-compliance
- Alcohol withdrawal
- Eclampsia
- Stroke



Pearls

- IM Midazolam is effective in the termination of seizures. Do not delay IM administration to obtain IV or IO access in an actively seizing patient.
- For a seizure that begins in the presence of EMS, if the patient was previously conscious, alert and oriented, take the time to assess and protect the patient and providers and CONSIDER THE CAUSE. The seizure may stop, especially in patients who have prior history of self-limiting seizures. However, do not hesitate to treat recurrent or prolonged (> 1 minute) seizure activity.
- Limit IN administrations to ½ dose in each nare.
- Status Epilepticus is defined as two or more successive seizures without a period of consciousness or recovery, or one prolonged seizure lasting longer than 5 minutes. This is a true emergency requiring rapid airway control, treatment, and transport.
- Grand Mal seizures (generalized) are associated with a loss of consciousness, incontinence, and oral trauma.
- Focal seizures (Petit Mal) affect only a part of the body and are not associated with a loss of consciousness.
- Assess the possibility of occult trauma and substance abuse.
- Be prepared for airway problems and continued seizures.
- Be prepared to assist ventilations or manage the airway, especially if Midazolam is used.