

Eye Problem - Unspecified

For any pain or problem of the eye or periorbital region, use with primary impression Traumatic Injury if a traumatic mechanism

History

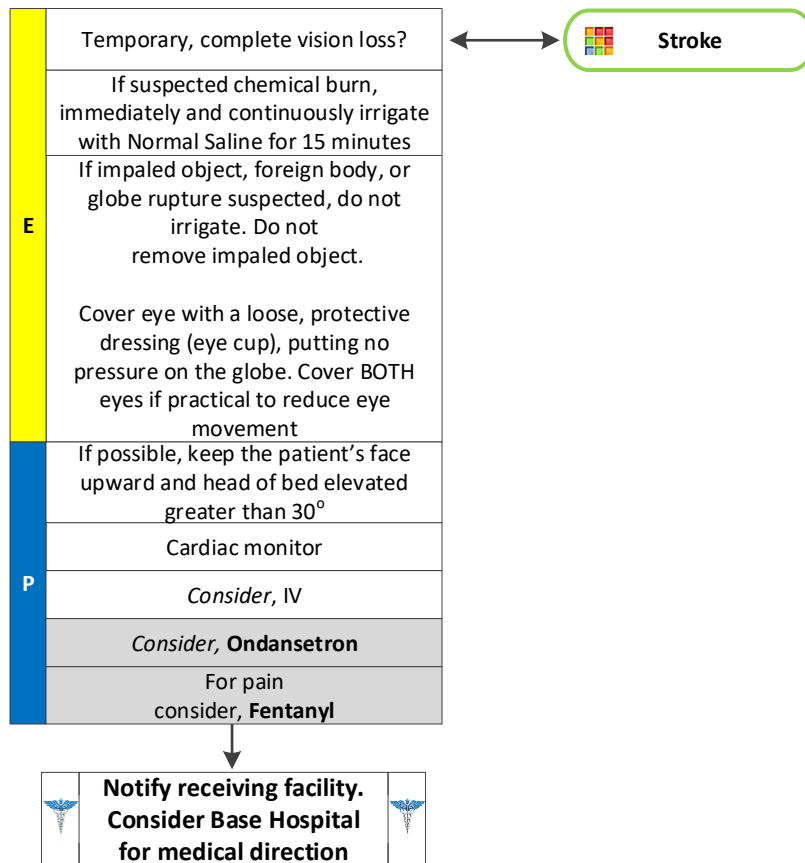
- Age
- Past medical history (glaucoma or retinal detachment)
- Medications (HTN, anticoagulants, aspirin, NSAIDs)
- Trauma or exposure to chemicals
- Time of injury
- Onset of symptoms
- Previous eye surgery, including LASIX
- Contact lenses

Signs and Symptoms

- Decreased or blurred vision
- Floaters/flushes/curtain coming down
- Onset moving from dark to bright
- Avulsion
- Orbital edema or contusion
- Deformed pupil
- Burning/pain to eye(s)
- Red eye/sclera
- Nausea or vomiting
- Pain with extraocular movement

Differential

- Glaucoma
- Retinal detachment
- Multi-system trauma
- Head trauma
- Orbital cellulitis
- Chemical burn
- Welding burn
- Corneal abrasion
- Conjunctivitis
- Parasite



Adult Medical Treatment Protocols

Pearls

- Suspect an eye injury if any significant facial trauma.
- Normal Saline is the preferred solution for irrigation, but sterile water may be used if Normal Saline is not immediately available.
- If globe rupture is suspected (high velocity mechanism, impaled object, irregular pupil, significantly decreased vision in the acute setting), the eye should be protected from environment and NO irrigation should be administered.
- Do not remove impaled objects. Protect them from movement with a protective dressing (eye cup) and cover BOTH eyes to reduce eye movement. Explain to patient that the injured eye moves with the other eye and movement can worsen injury.
- Protect the patient from further eye injury/increases in intraocular pressure by elevating the head of the gurney, keeping the patient's face upward, consider Ondansetron for nausea.

