

Pediatric Respiratory Distress/Bronchospasm

For asthma exacerbations, epiglottitis and any bronchospasms/wheezing not from pulmonary edema

History

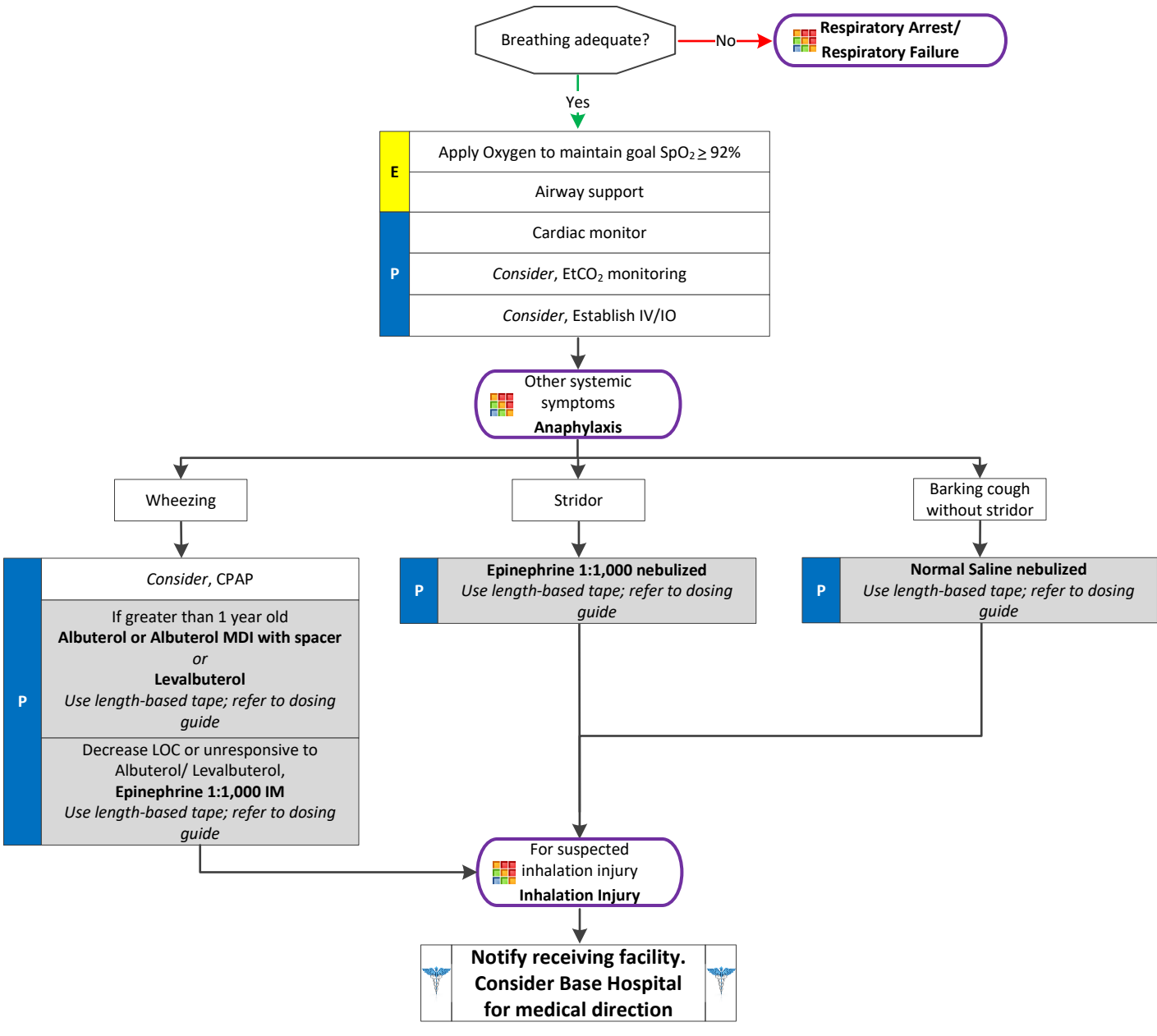
- Asthma
- COPD – chronic bronchitis, emphysema
- Home treatment (e.g., oxygen or nebulizer)
- Medications (e.g., Theophylline, steroids, inhalers)
- Frequency of inhaler use

Signs and Symptoms

- Shortness of breath
- Pursed lip breathing
- Decreased ability to speak
- Increased respiratory rate and effort
- Wheezing or rhonchi/diminished breath sounds
- Use of accessory muscles
- Cough
- Tachycardia

Differential

- Asthma
- Anaphylaxis
- Foreign body aspiration
- Partial airway obstruction (i.e. epiglottitis)
- Croup
- Pleural effusion
- Pneumonia
- Pulmonary embolus
- Pneumothorax
- Cardiac (MI or CHF)
- Pericardial tamponade
- Hyperventilation
- Inhaled toxin (e.g., carbon monoxide, etc.)



Pediatric Respiratory Distress Treatment Protocols

Pediatric Respiratory Distress/Bronchospasm

For asthma exacerbations, epiglottitis and any bronchospasms/wheezing not from pulmonary edema

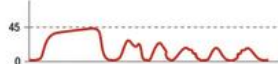Sudden loss of waveform

- ET tube disconnected, dislodged, kinked or obstructed
- Loss of circulatory function



Decreasing EtCO₂

- ET tube cuff leak
- ET tube in hypopharynx
- Partial obstruction



CPR Assessment

- Attempt to maintain minimum of 10mmHg



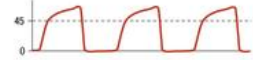Sudden increase in EtCO₂

- Return of spontaneous circulation (ROSC)

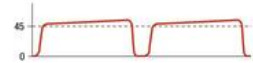

Bronchospasm ("Shark-fin" appearance)

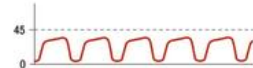
- Asthma
- COPD



Hypoventilation

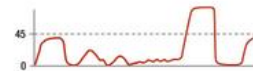

Hyperventilation



Decreased EtCO₂

- Apnea
- Sedation



Factors Affecting EtCO₂

Causes of Elevated EtCO₂

METABOLISM

- Pain
- Hyperthermia
- Shivering

RESPIRATORY SYSTEM

- Respiratory insufficiency
- Respiratory depression
- COPD
- Analgesia/ sedation

CIRCULATORY SYSTEM

- Increased cardiac output

MEDICATIONS

- Bicarbonate administration

Causes of Decreased EtCO₂

METABOLISM

- Hypothermia
- Metabolic acidosis

RESPIRATORY SYSTEM

- Alveolar hyperventilation
- Bronchospasm
- Mucus plugging

CIRCULATORY SYSTEM

- Hypotension
- Sudden hypovolemia
- Cardiac arrest
- Pulmonary emboli

Pearls

- A silent chest in respiratory distress is a pre-respiratory arrest sign.
- Diffuse wheezing in patients < 1 year, it is almost always bronchiolitis, not asthma. For these patients, suctioning and supplemental oxygen are appropriate treatments.
- Pulse oximetry monitoring is required for all respiratory patients.

