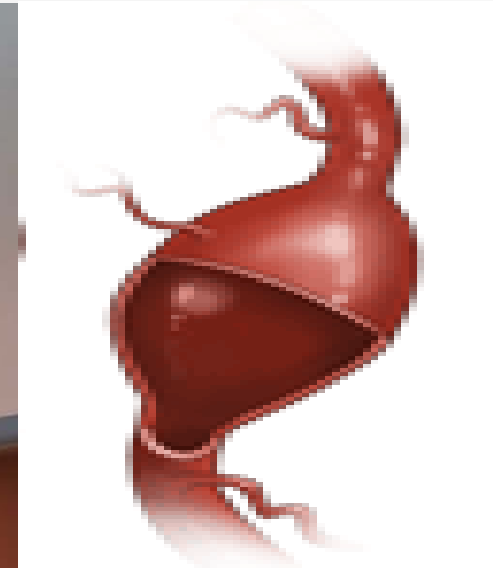
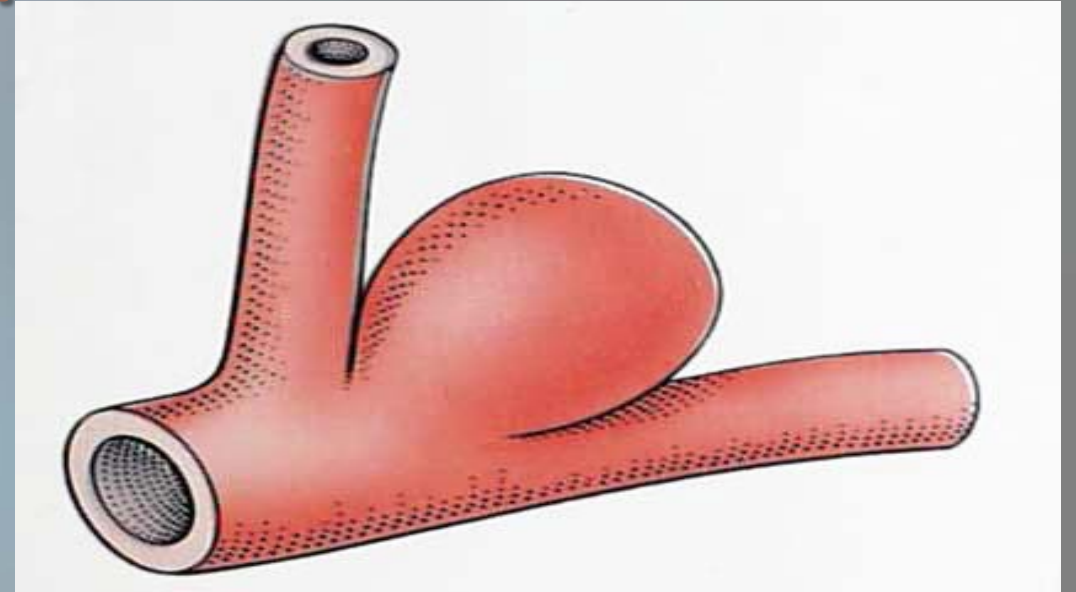


# Coiling Versus Clipping of Intracranial Aneurysms

Prasad Reddy, MD

# What is a cerebral aneurysm?

- A dilation of an artery in the brain that results from a weakening of the muscular layer (tunica media) of a blood vessel wall.
  - Saccular (berry)
  - Fusiform



# Risk Factors

- Hypertension
- Cigarette smoking
- Family history of intracranial aneurysms
  
- Drug use
  - Cocaine
  - Methamphetamines

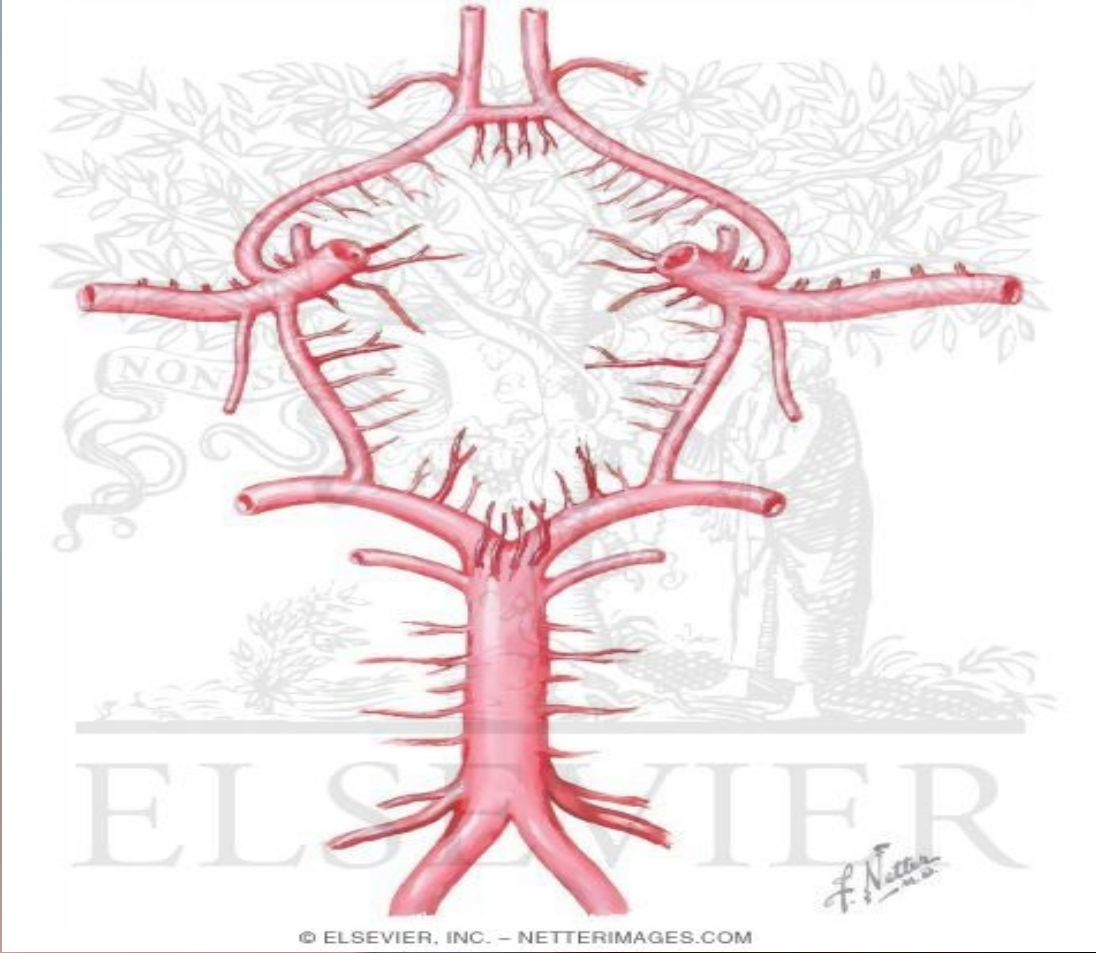
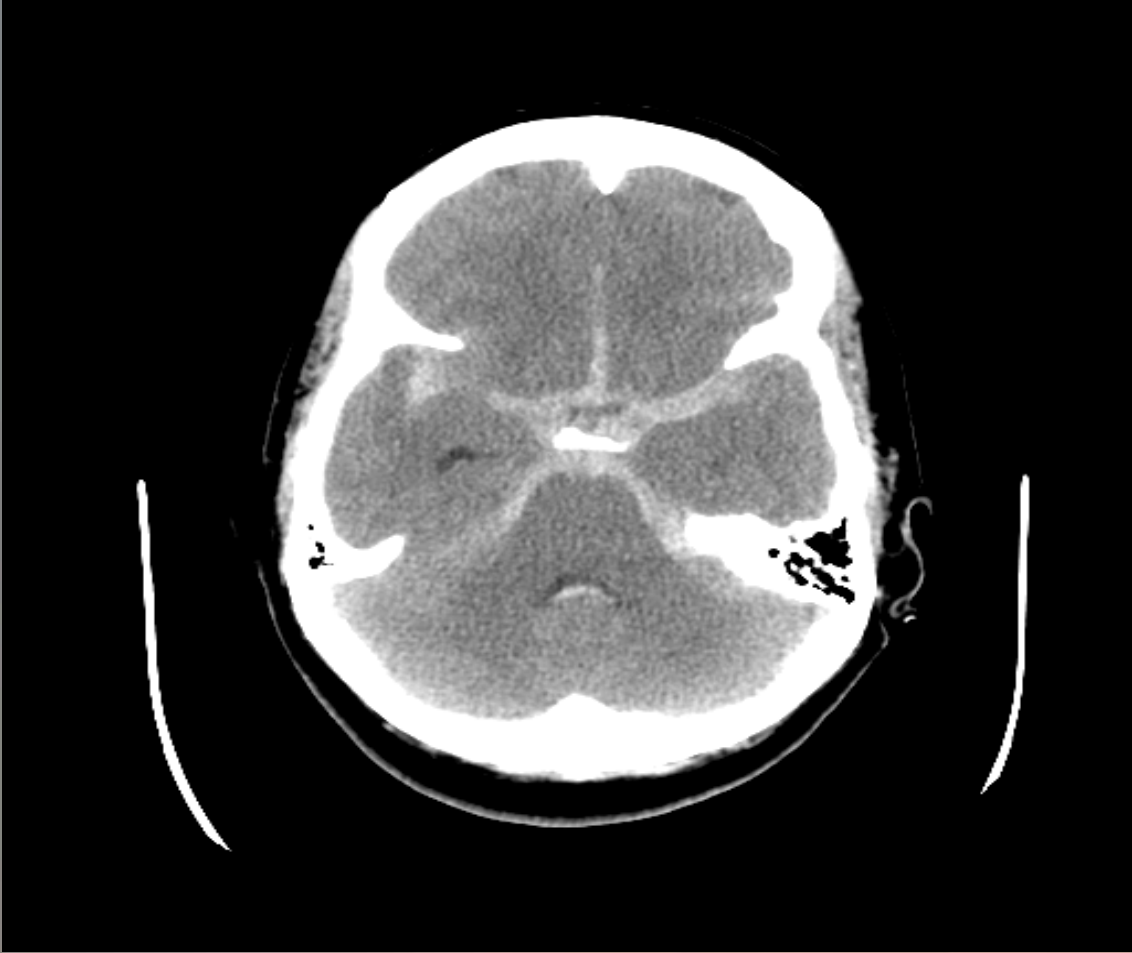# Other Risk Factors

- Connective tissue disorders
  - Ehlers-Danlos Syndrome
  - Marfan's Syndrome
  - Fibromuscular dysplasia
- Polycystic kidney disease
  - 15%
- Infection
- Trauma

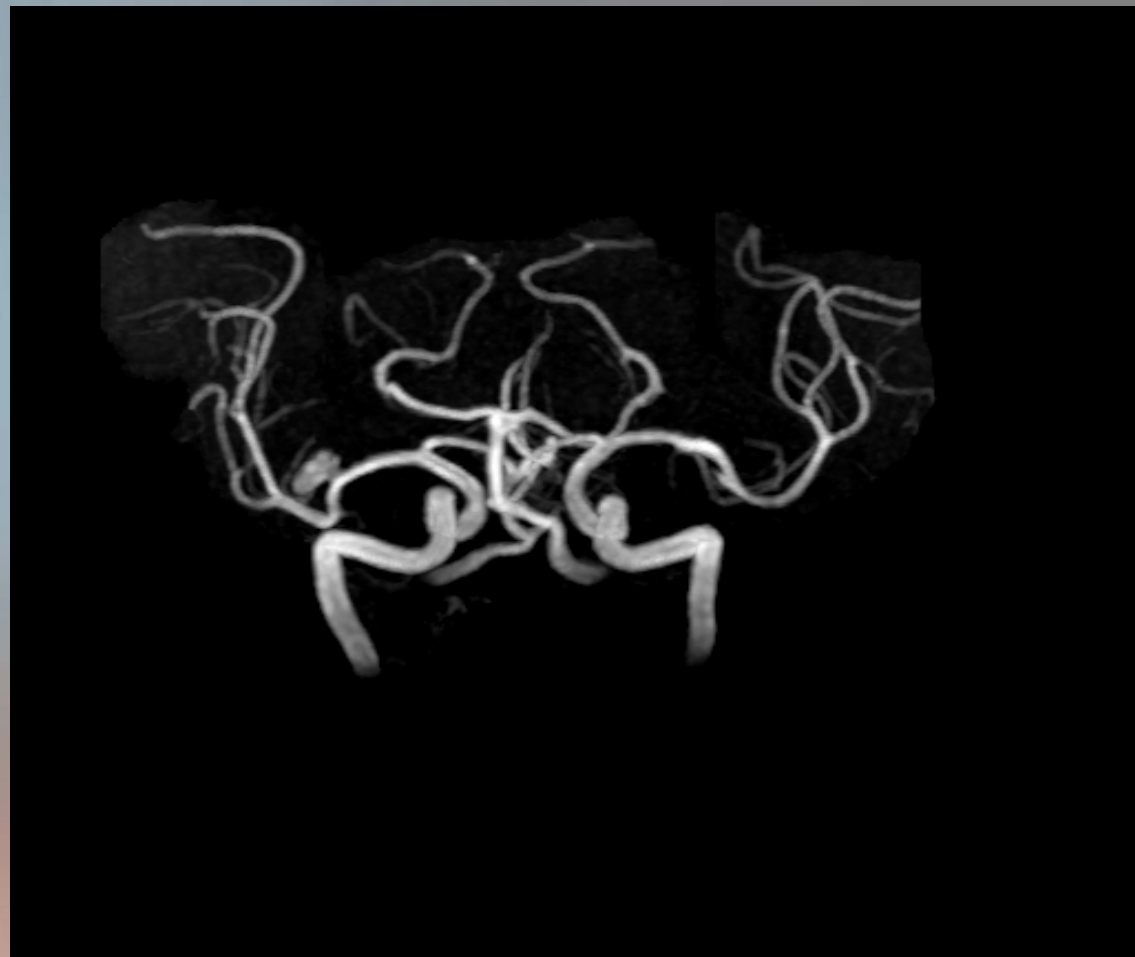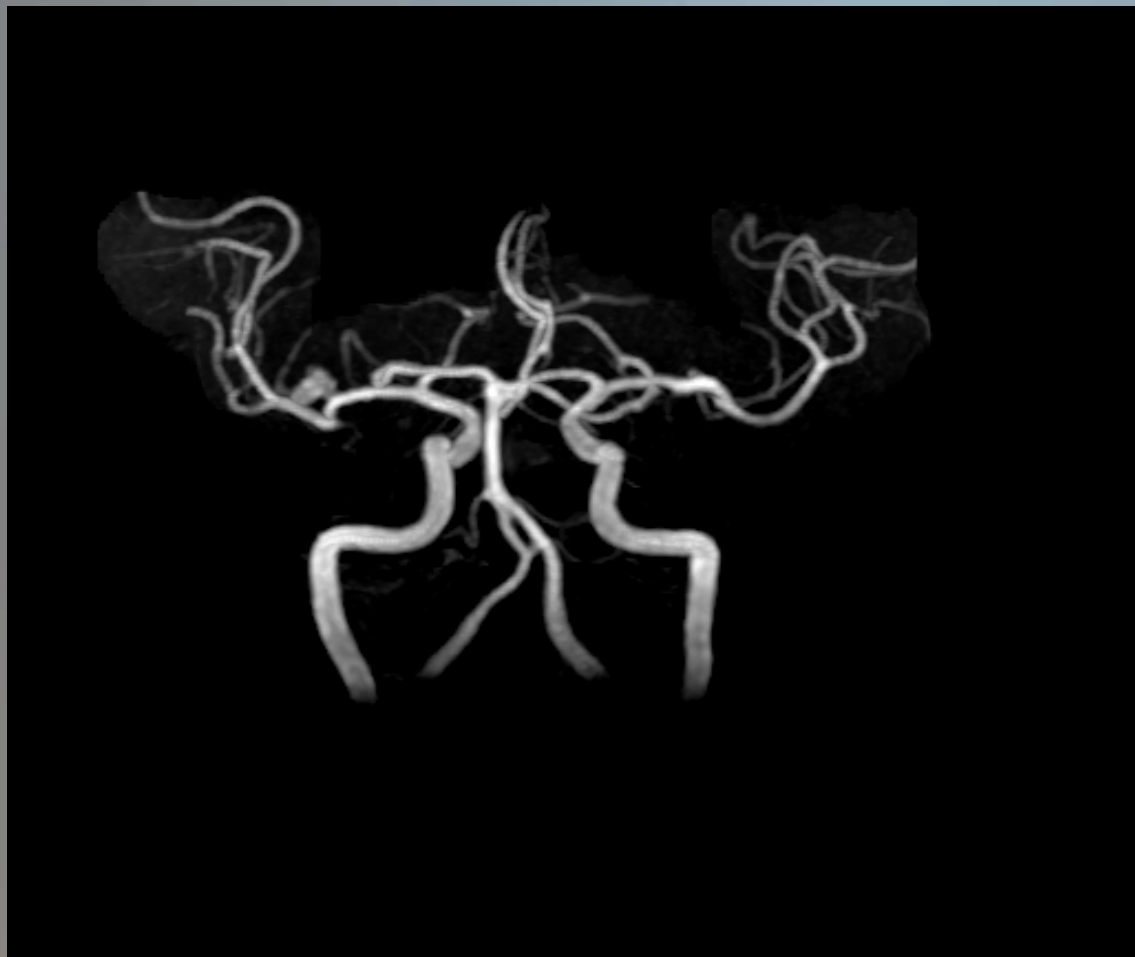# Prevalence

- 5%
- Age 40-60
- Female:Male ratio, 3:2
- 20% have multiple aneurysms
- Annual incidence of aneurysm rupture: 30,000 people (U.S.)
  - ~15% die before reaching hospital
  - Fatal in 40-50%

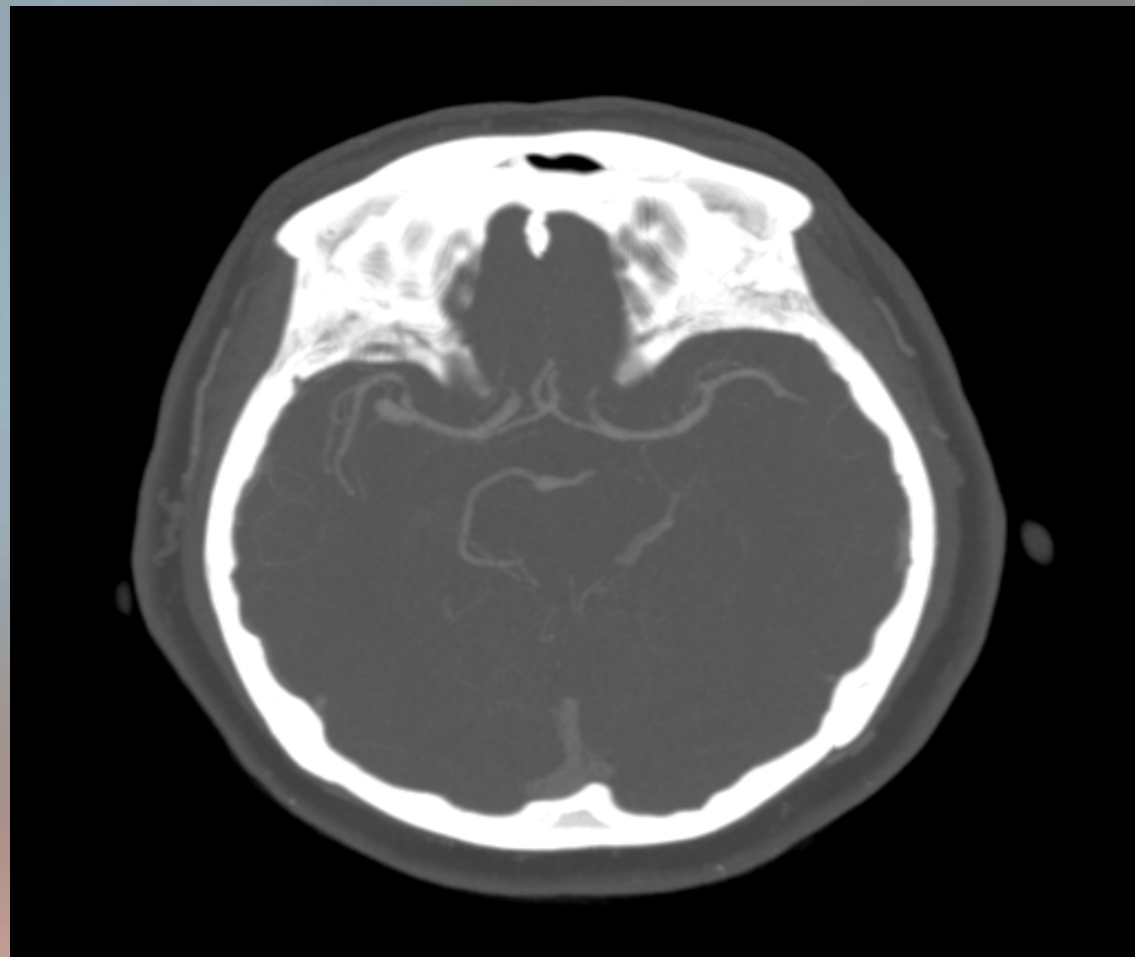
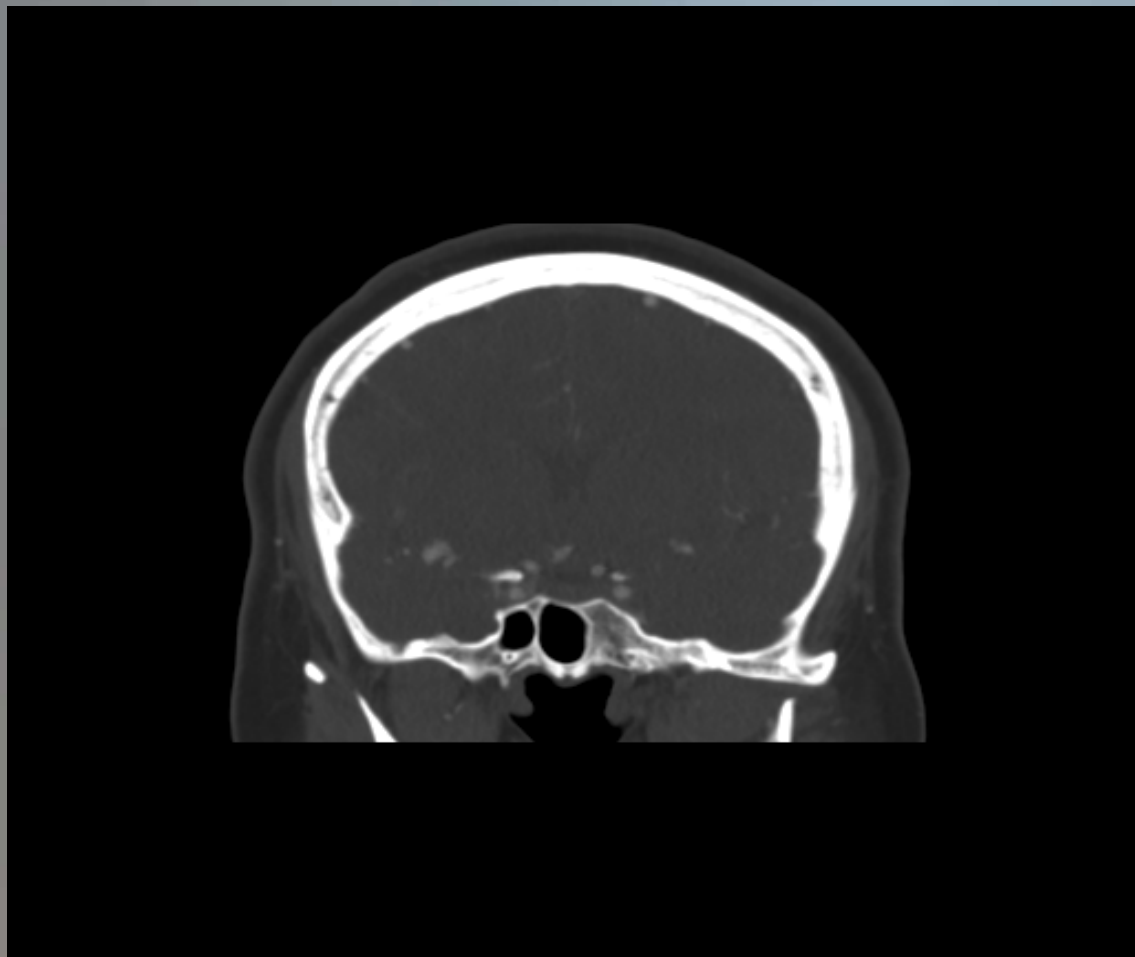# Subarachnoid Hemorrhage



# MRA

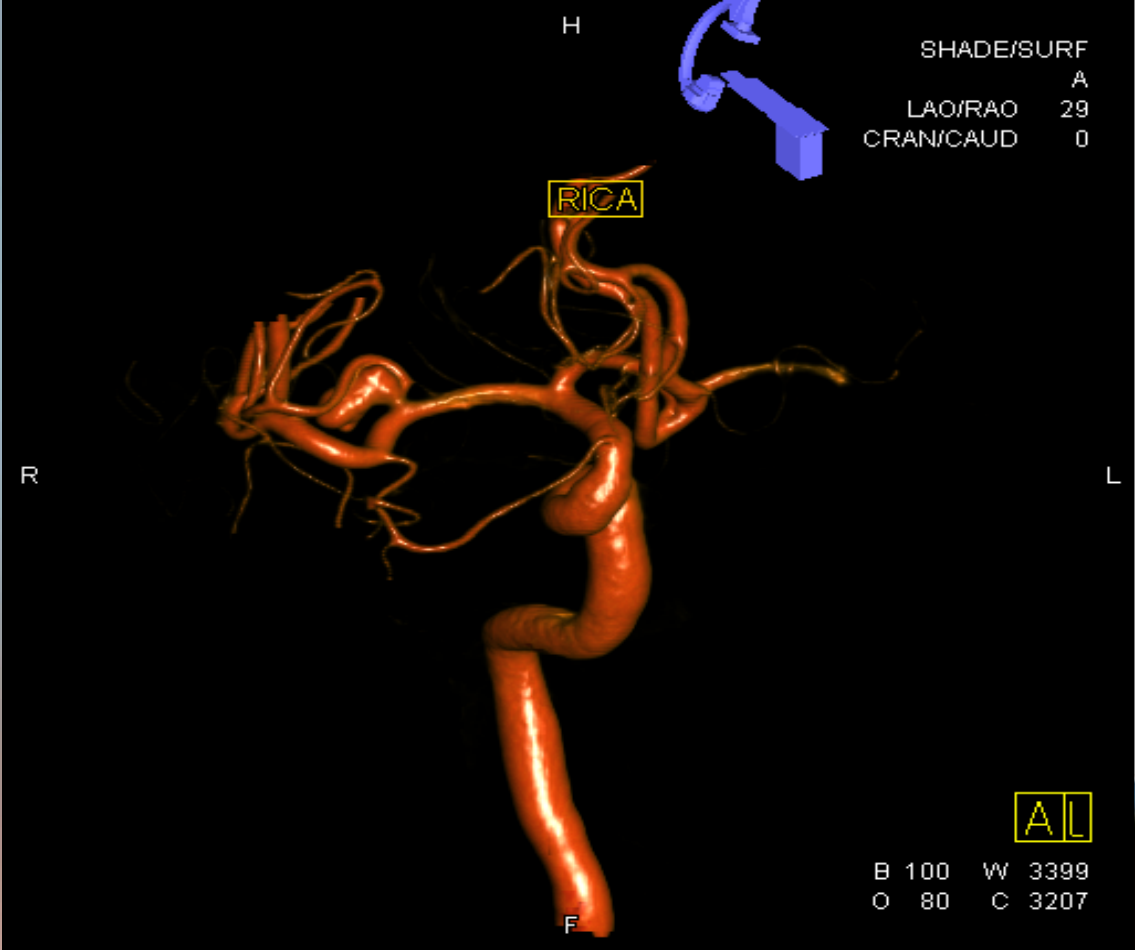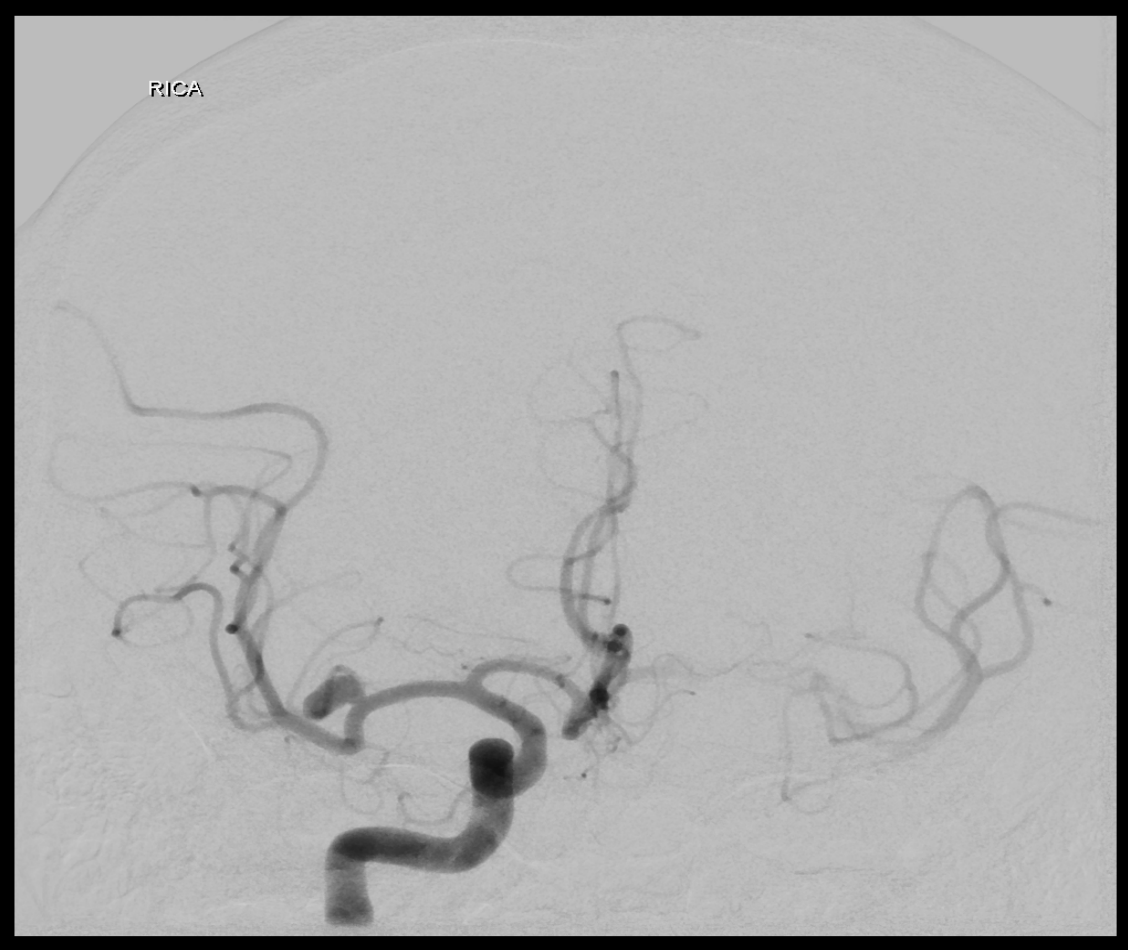


# CTA



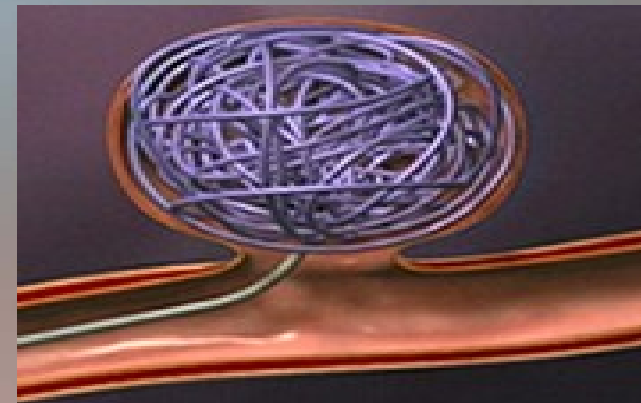
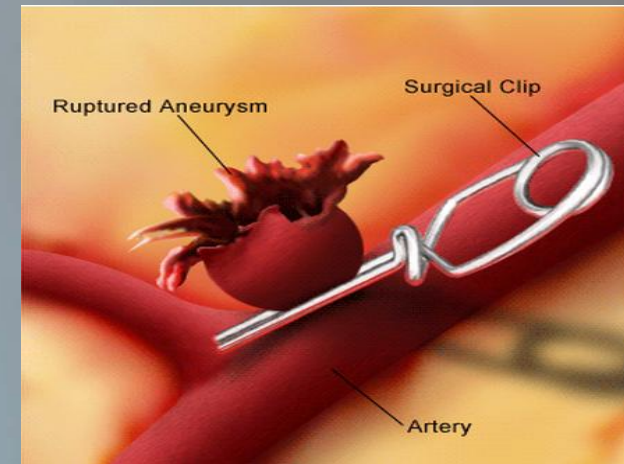


# Cerebral Angiogram



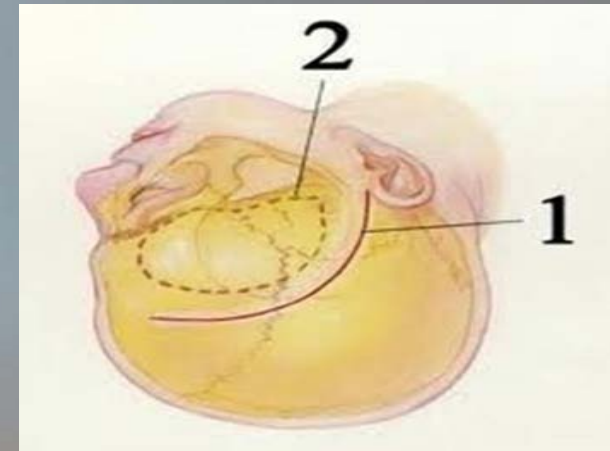
# Treatment

- Surgical
  - Craniotomy for clipping
    - Walter Dandy, 1937
  
- Endovascular
  - Coil embolization
    - Guido Guglielmi, 1991



# Clipping

- Incision
- Bone flap
- Dural opening
- Sylvian fissure dissection
- Proximal control
- Clipping
  - Intraoperative angiogram
- Closure



# Clipping

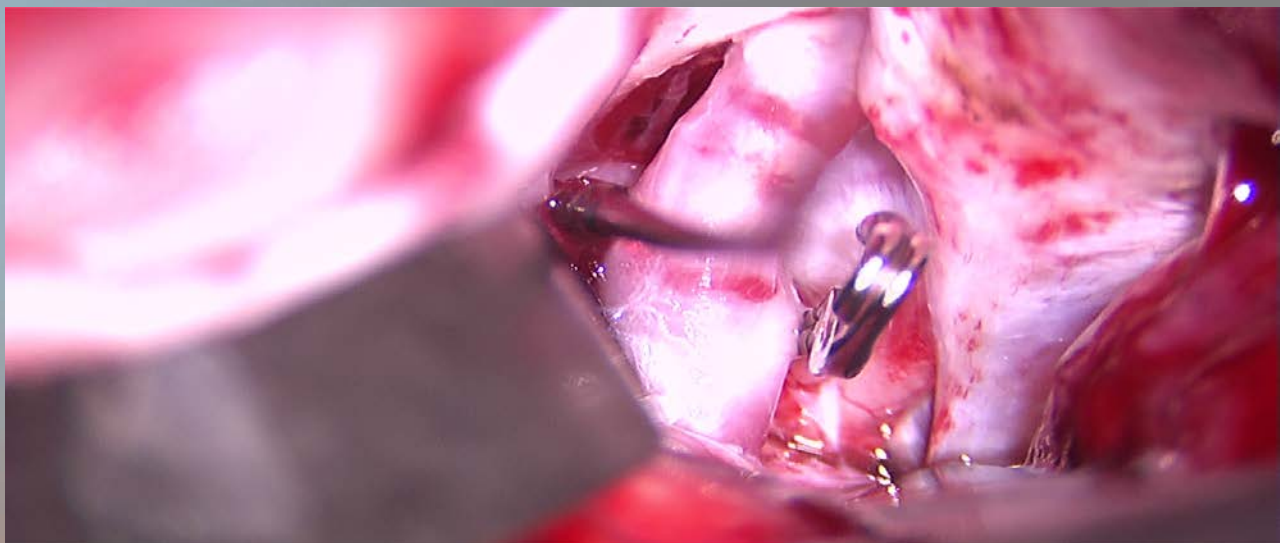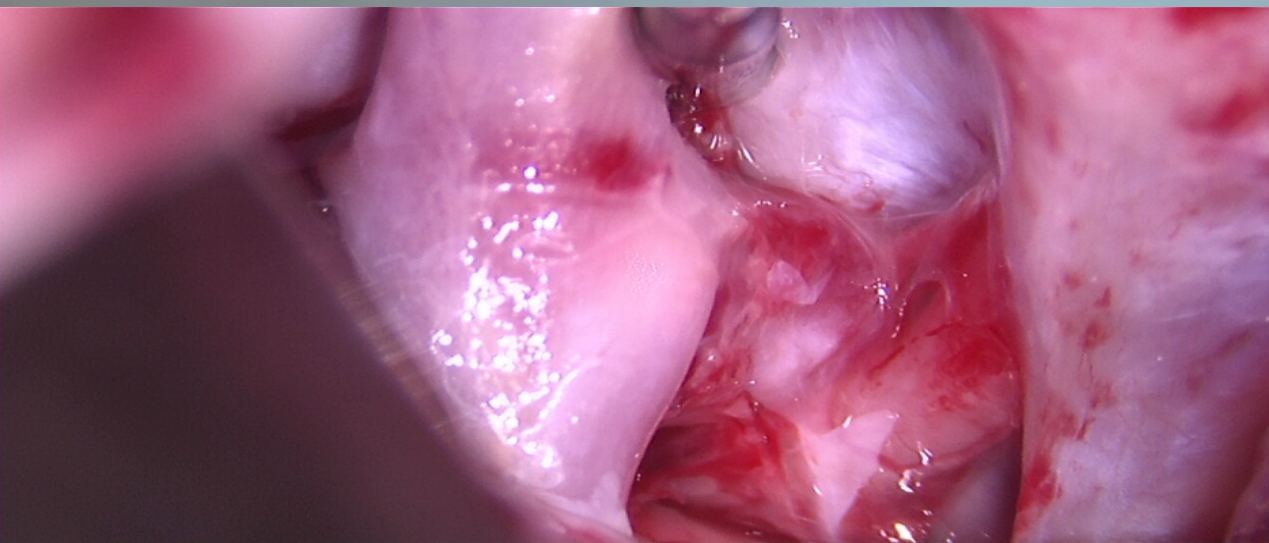
## Pros

- Definitive
- Durable
- 3-D visualization

## Cons

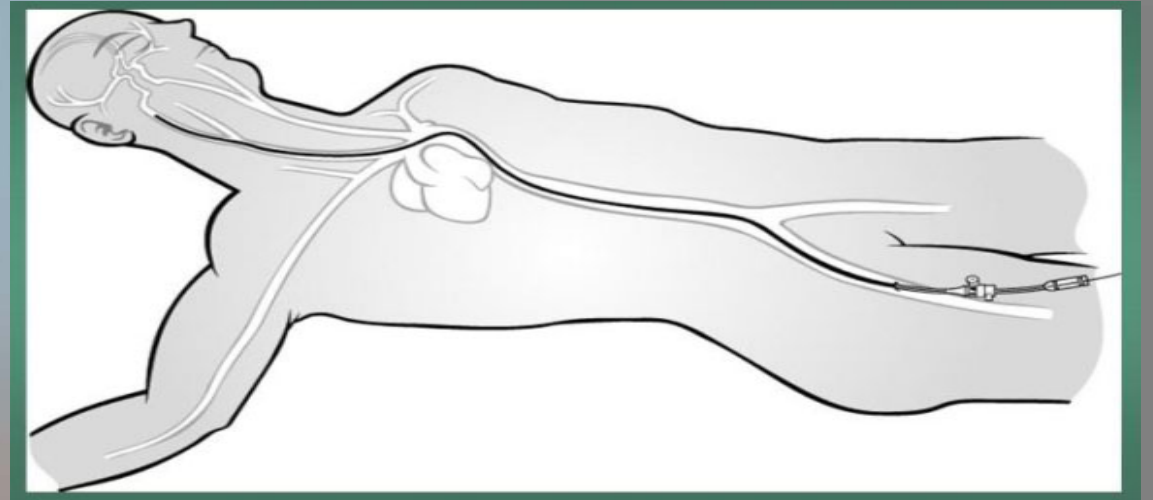
- Longer hospital stay
  - 1-4 days
- Post-operative pain

# Clipping of PCOM aneurysm



# Coiling

- Small groin incision
- Catheterization of femoral artery
  - Heparinization
- Guide catheter placement
- Catheterization of aneurysm
- Coil embolization
- Closure of arteriotomy



# Coiling

## Pros

- Tiny incision
- Minimal pain
- Shorter hospital stay
  - 1-2 days

## Cons

- Need for follow-up
  - Recanalization
  - Coil compaction
- 2-D visualization

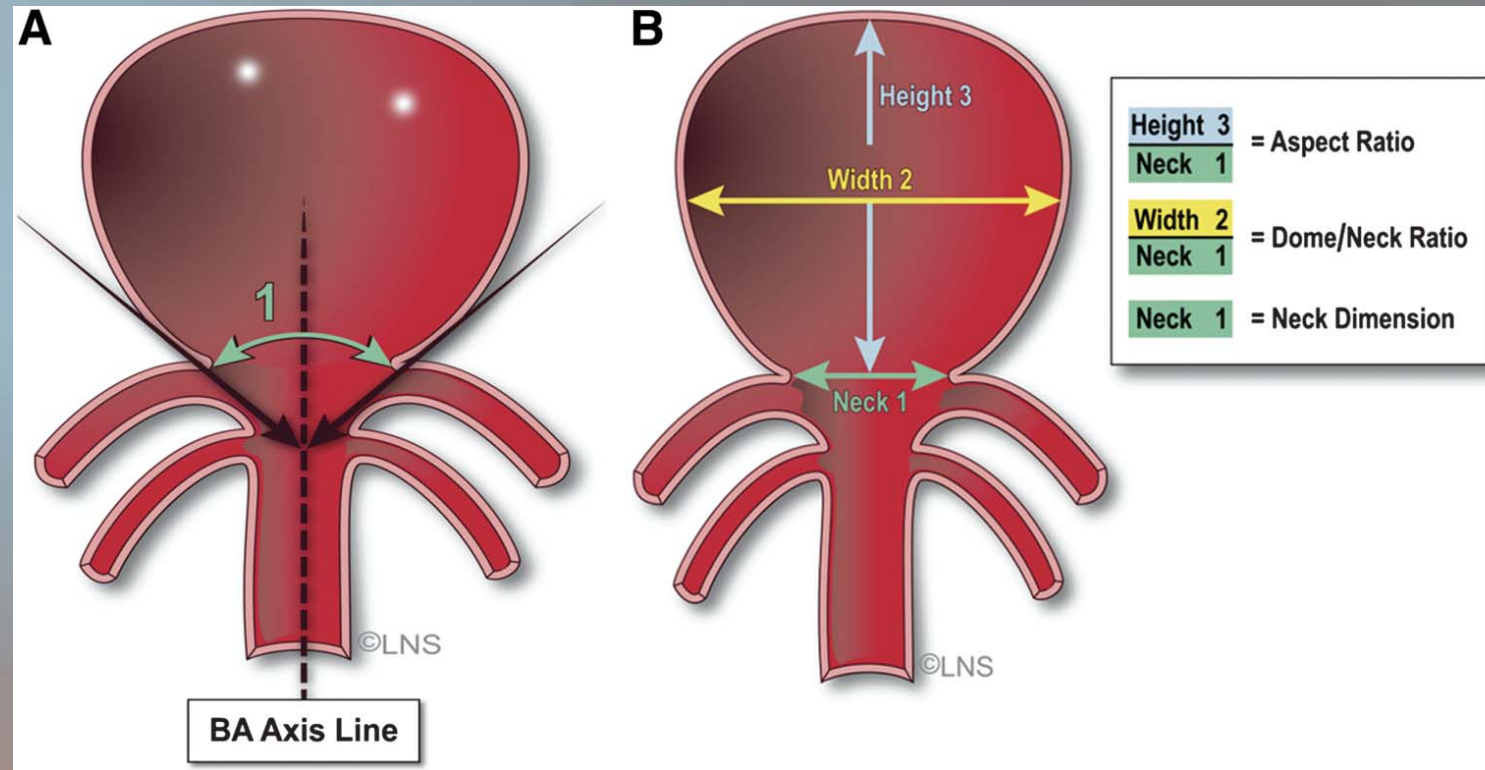
# Factors that favor clipping

- Younger age
- Middle cerebral artery (MCA) aneurysms
- Giant aneurysm (>2.5cm)
  - High recanalization rate with coiling
- Small aneurysms (<2mm)
- Wide necked aneurysms

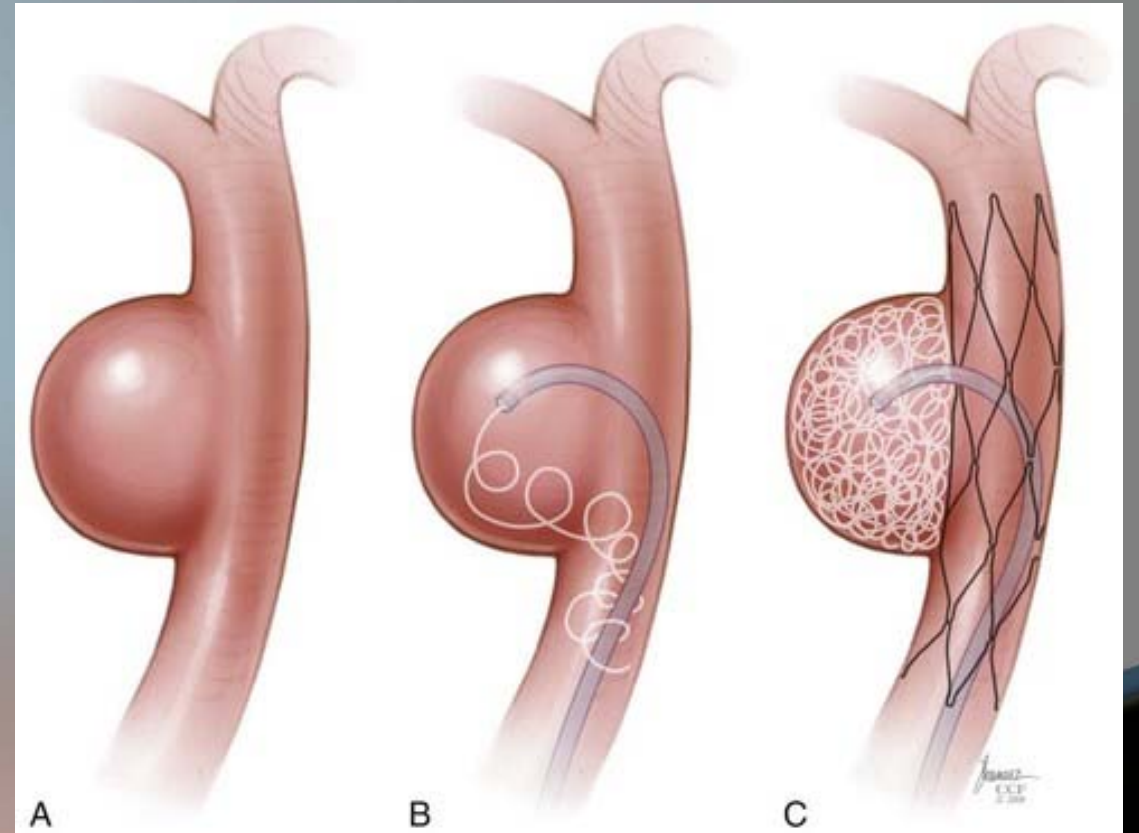
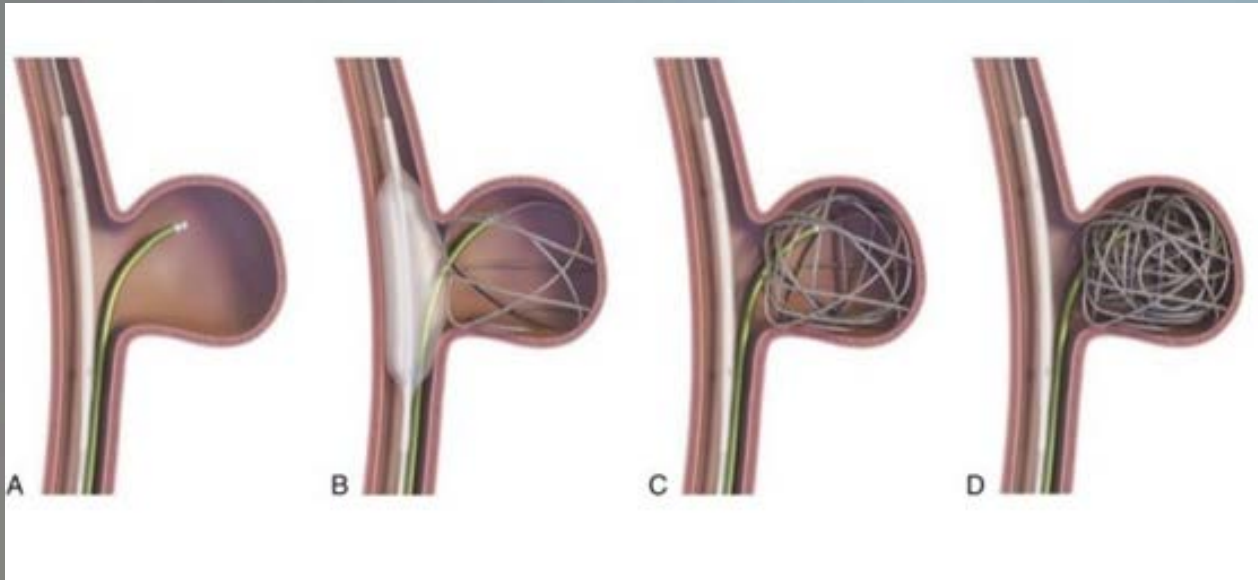


# Factors that favor coiling

- Elderly patients (>75 yrs)
- Poor clinical grade
- Aneurysm configuration
  - Dome-to-neck ratio  $\geq 2$
- Posterior circulation aneurysms
- Patients on Aspirin/Plavix

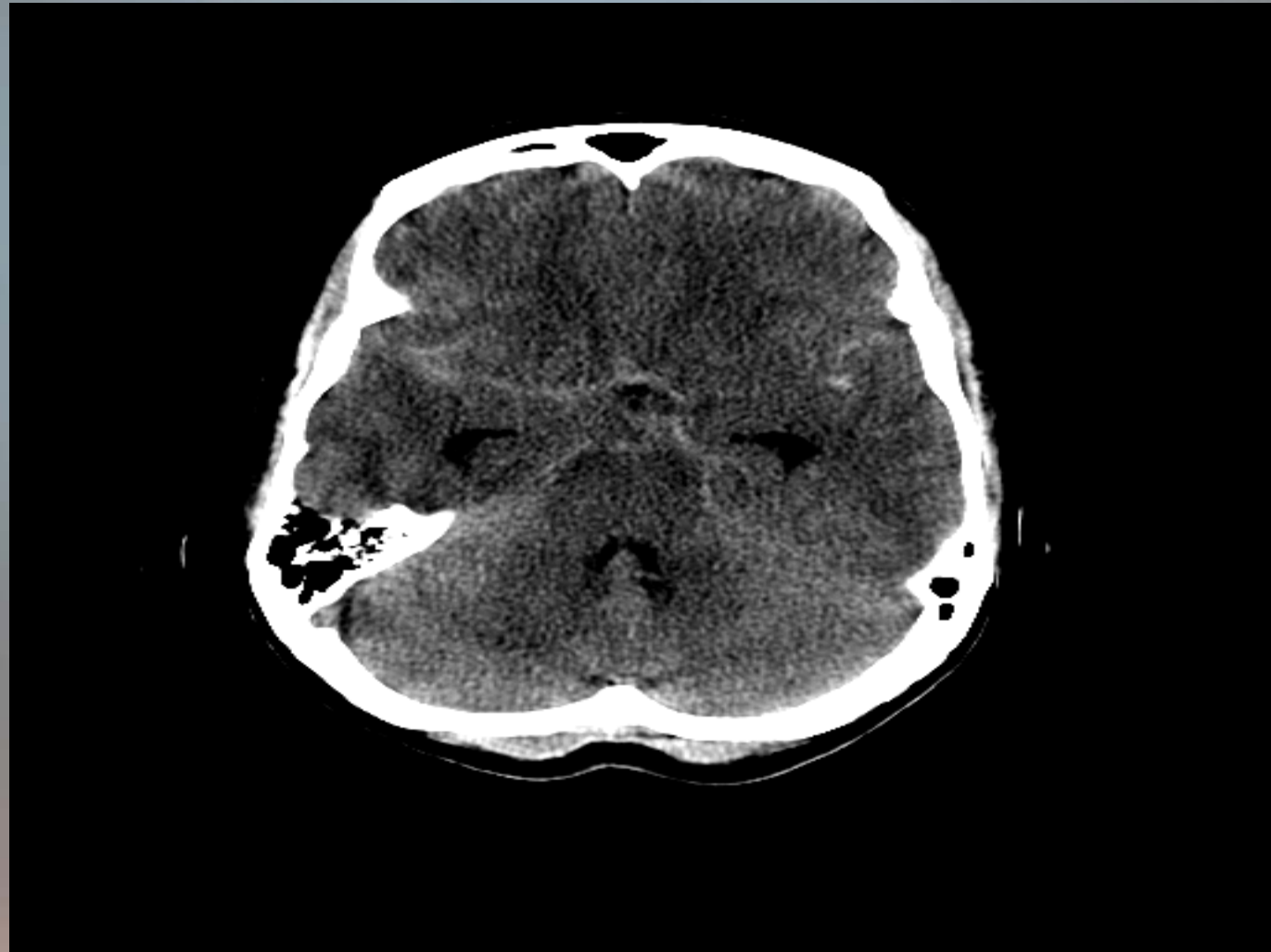


# Complex Coiling Techniques

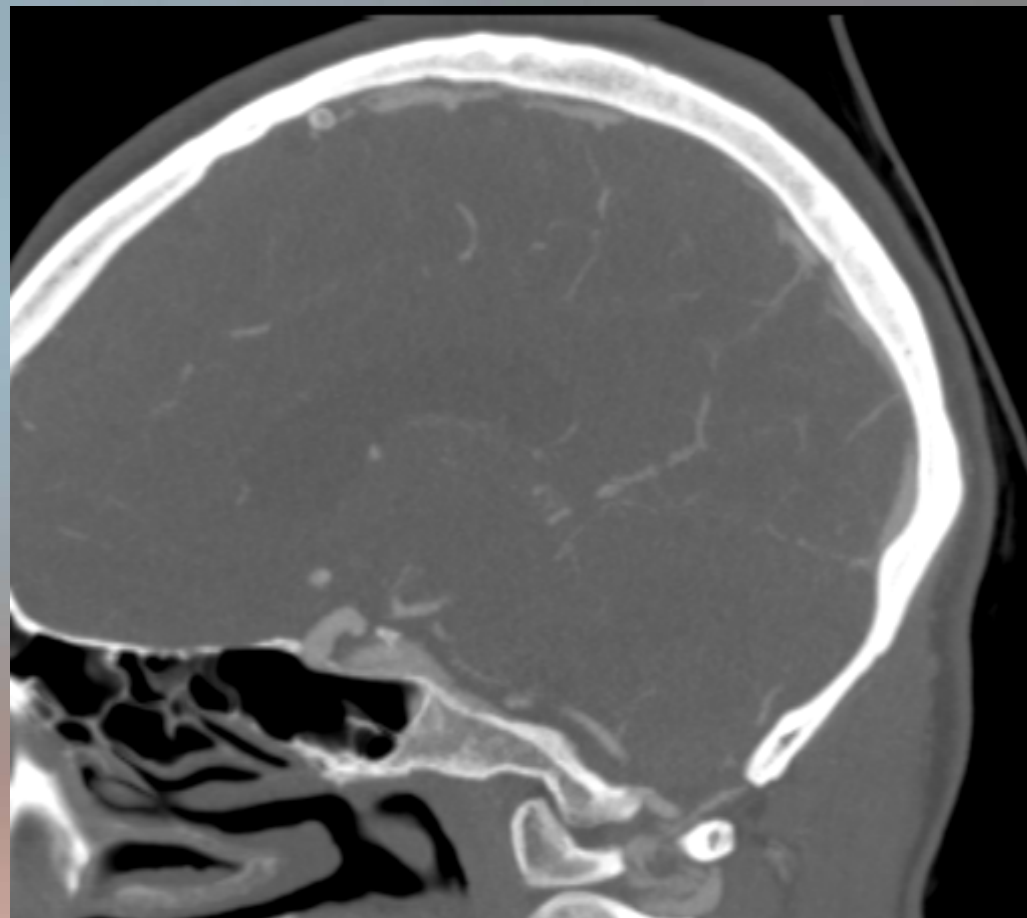
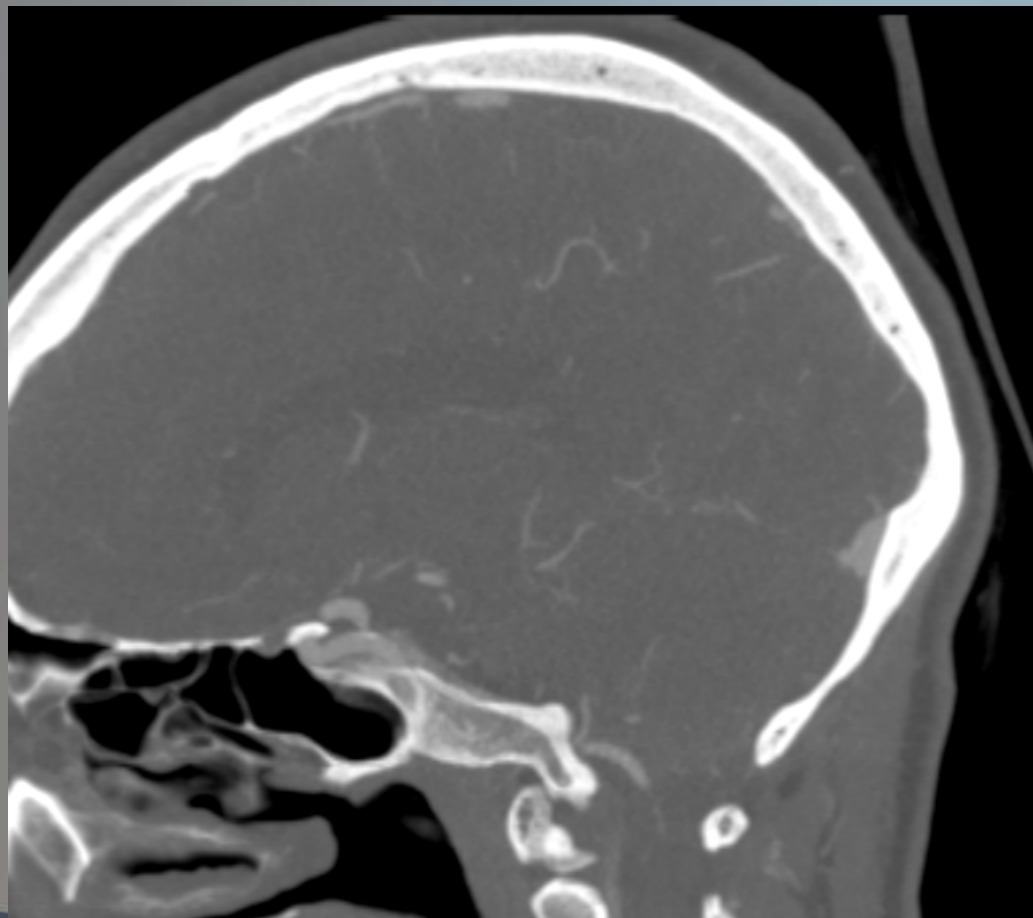


# Case #1

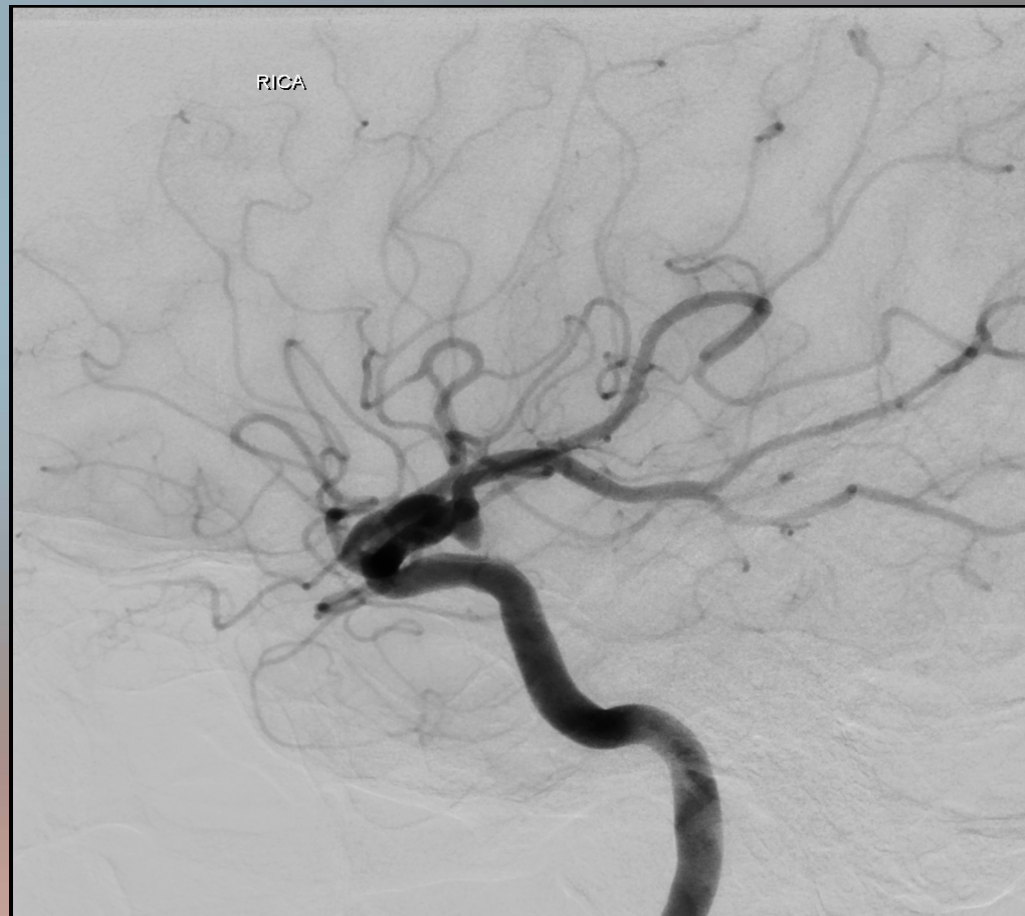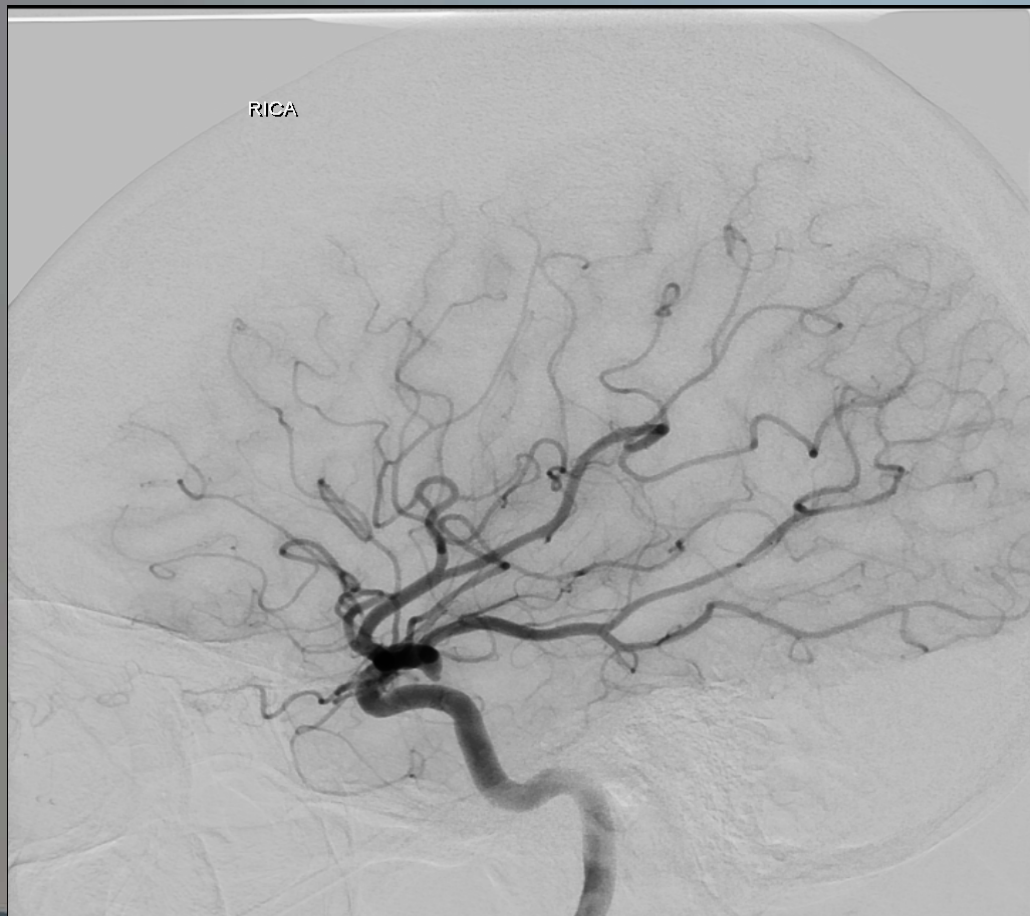
- 55 year old female
- Sudden onset worst headache of life during intercourse
  - Vomiting
  - Neck pain (meningismus)
  - Photophobia
- Past Medical History
  - Hypertension
  - Former smoker



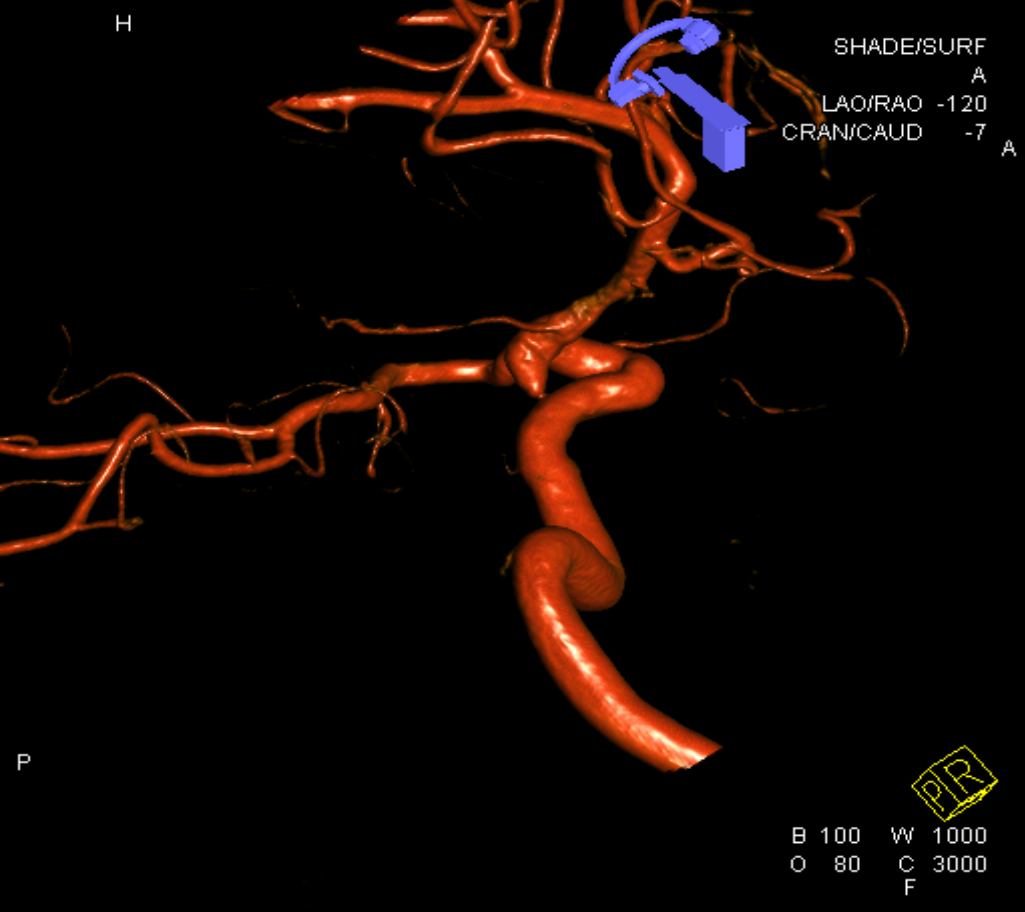
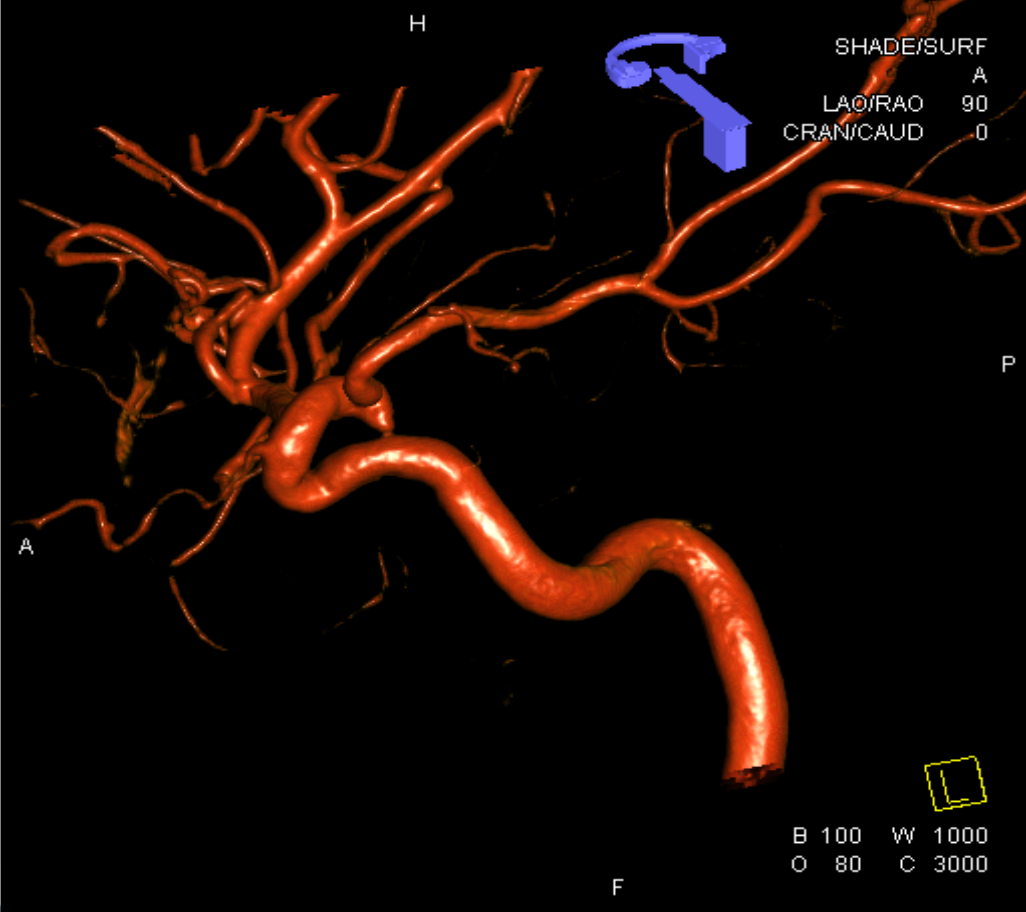
# CTA



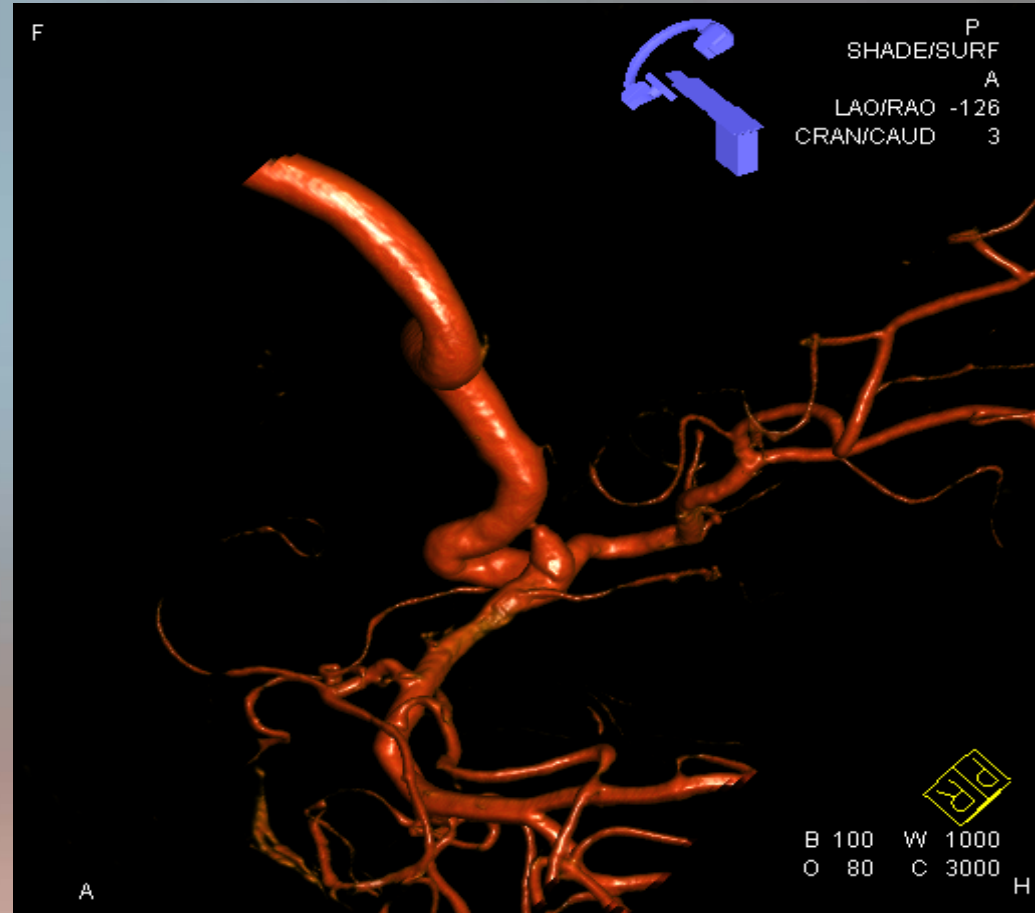
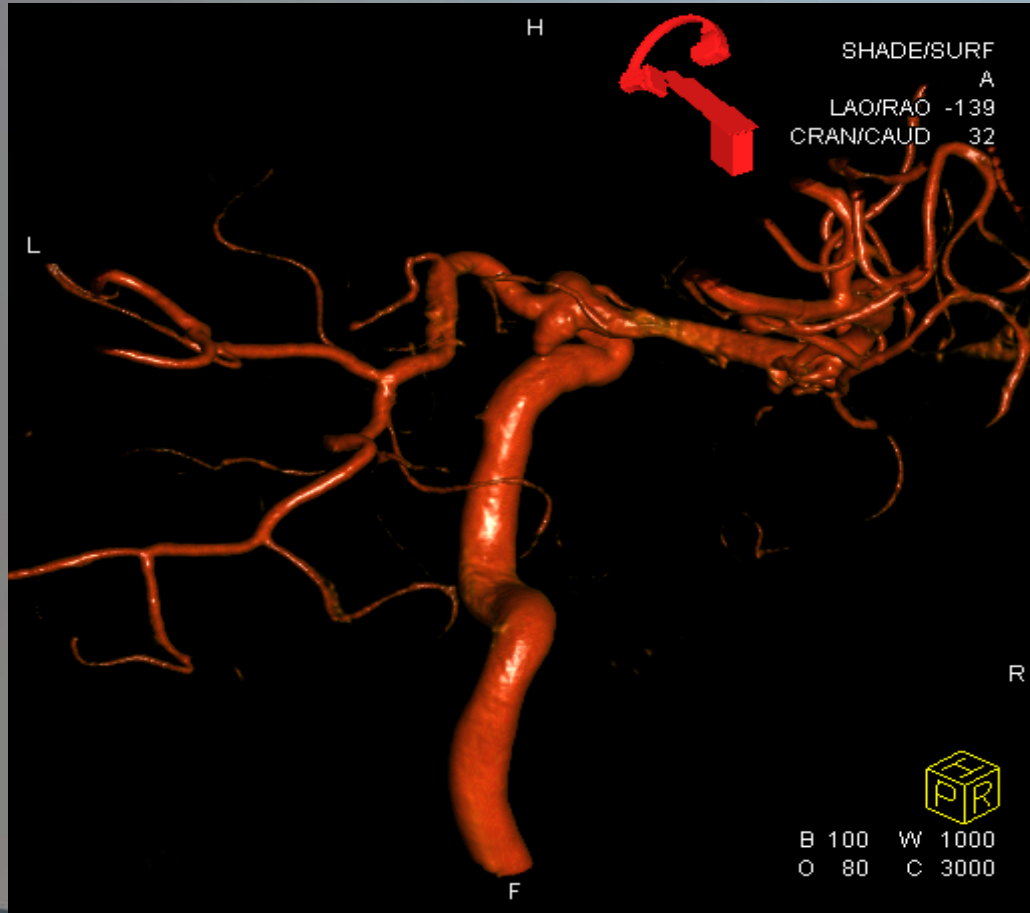# Angiogram



# 3D Angiogram

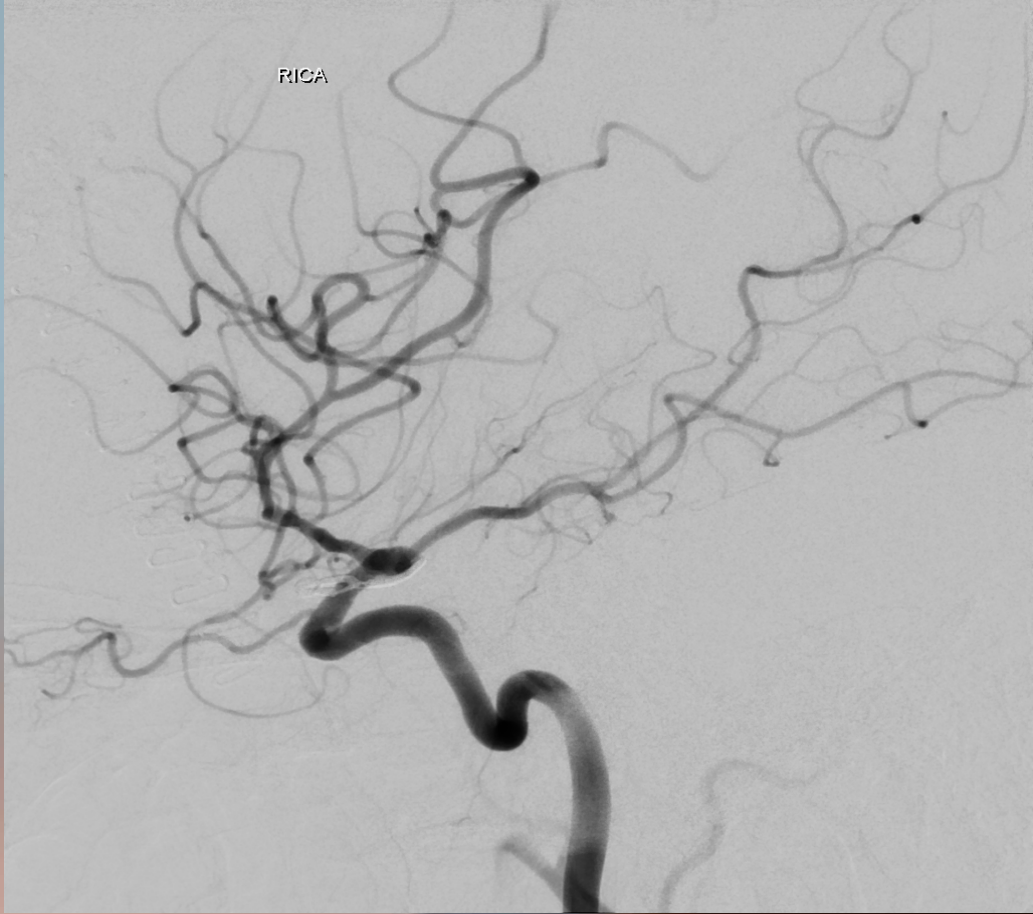
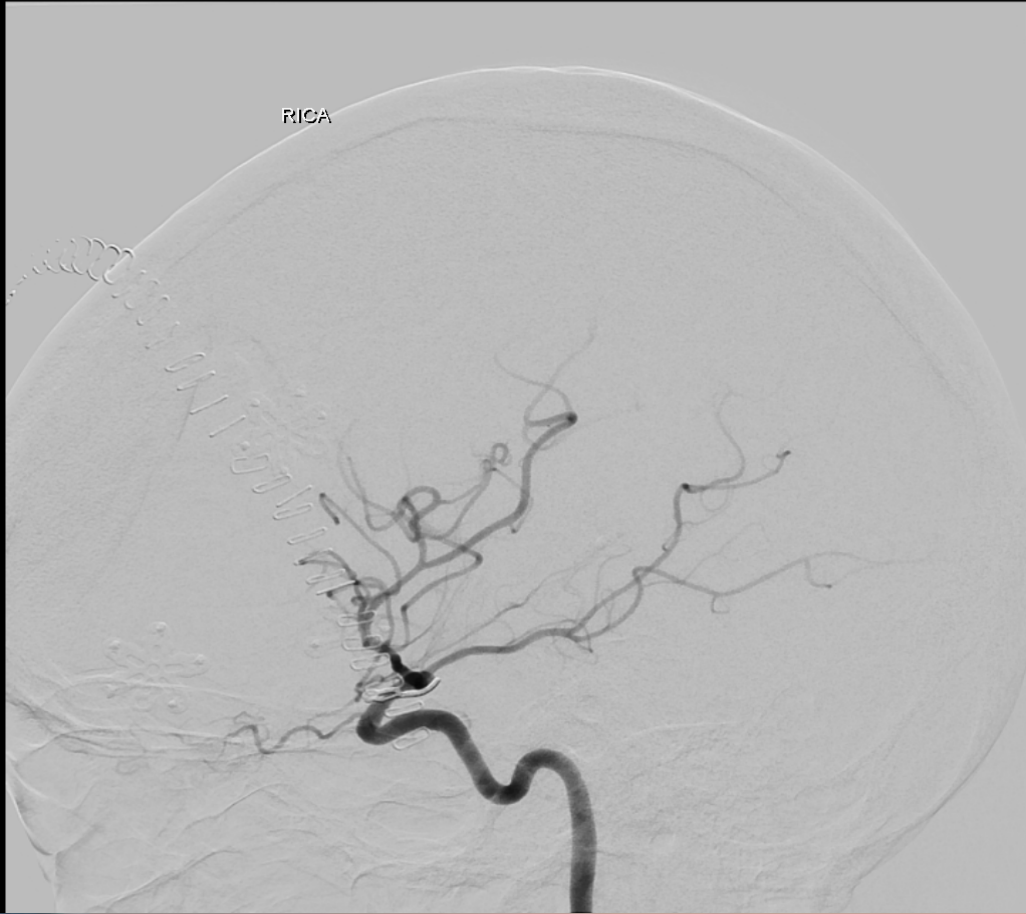


# 3D Angiogram

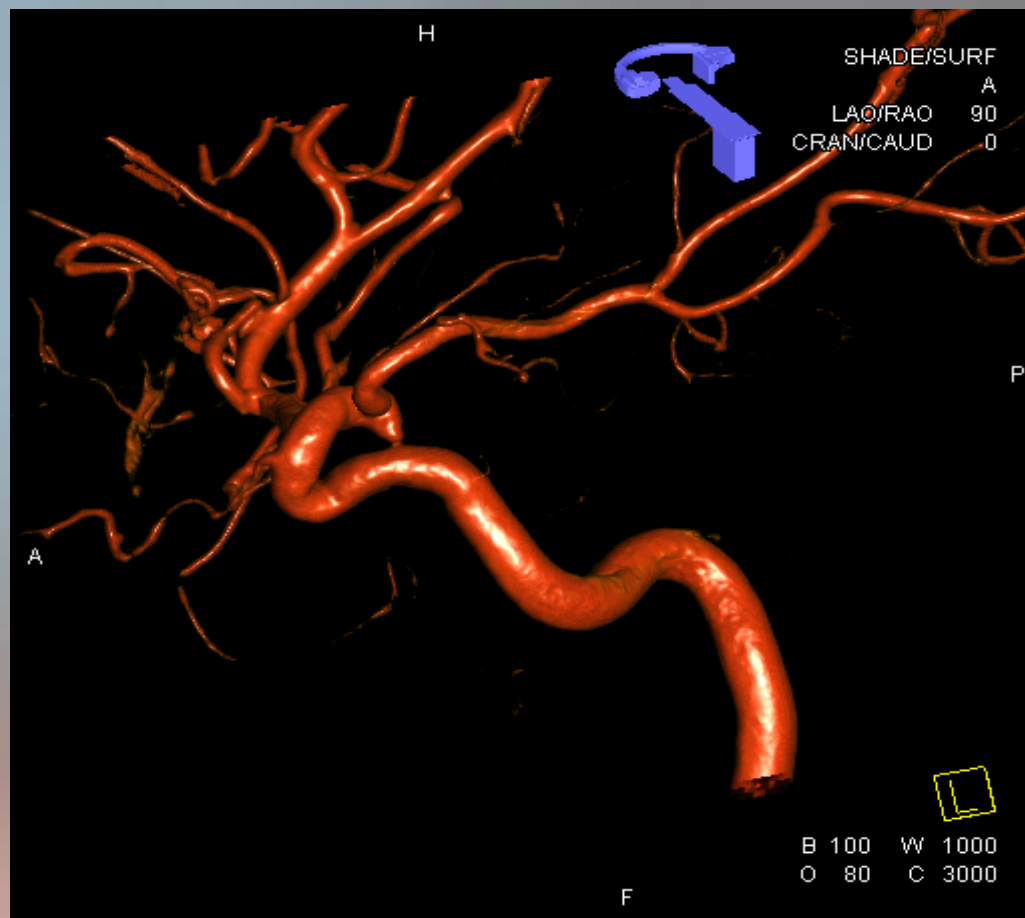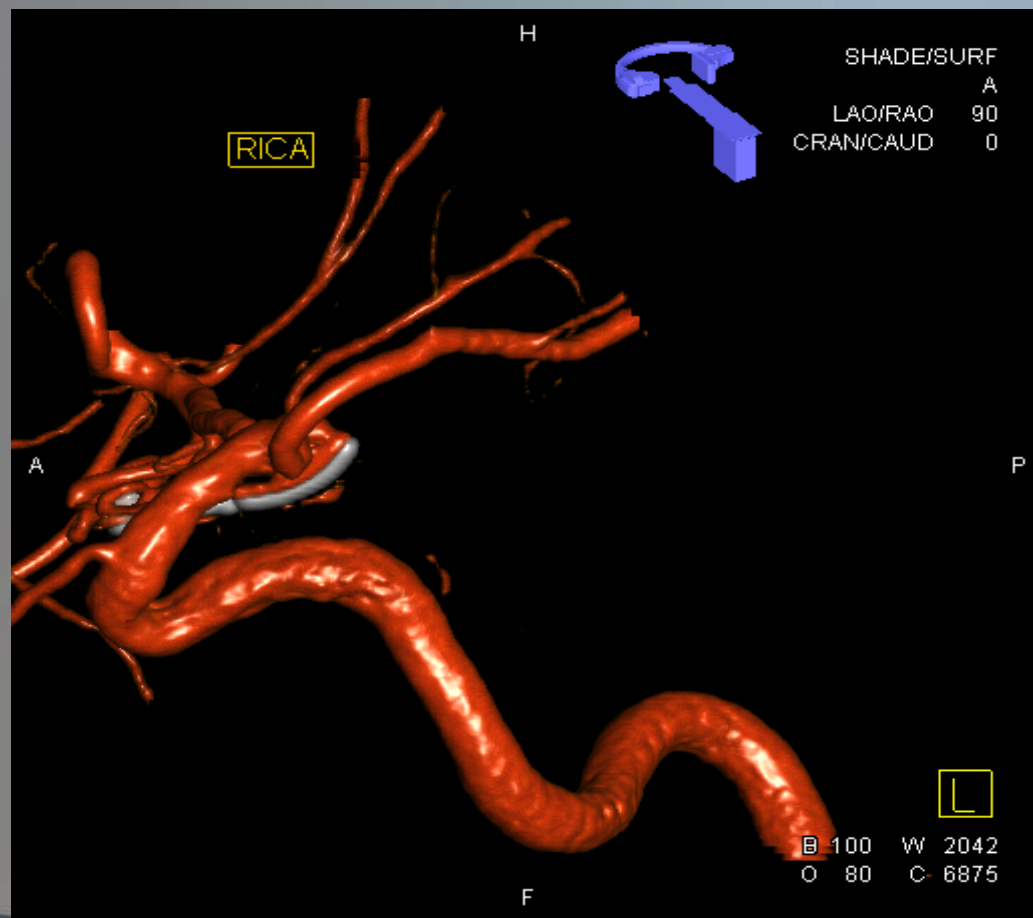




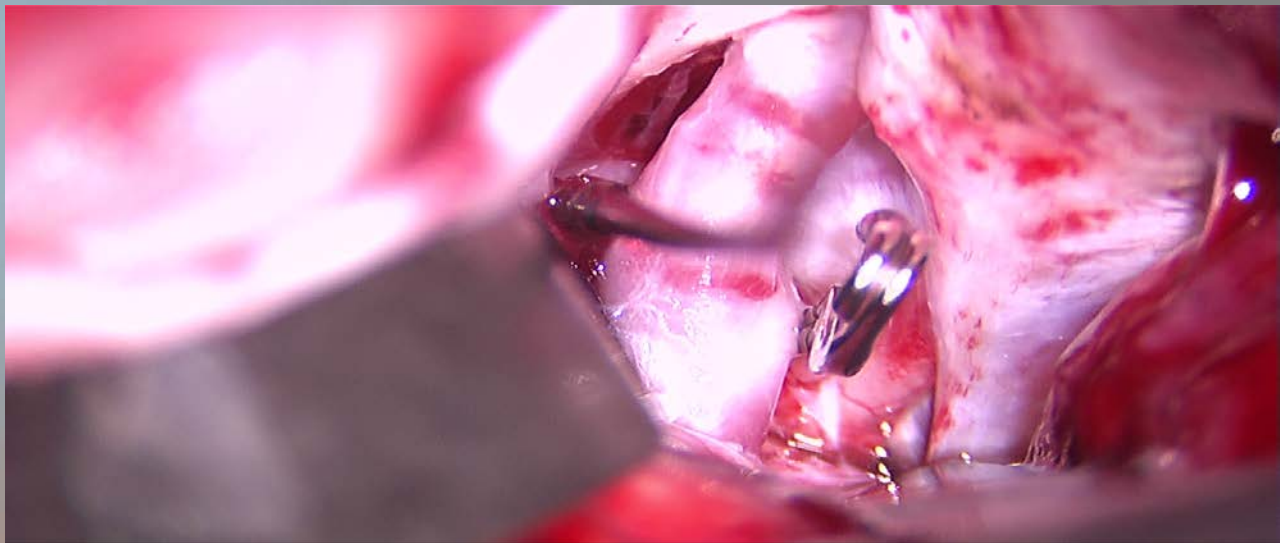
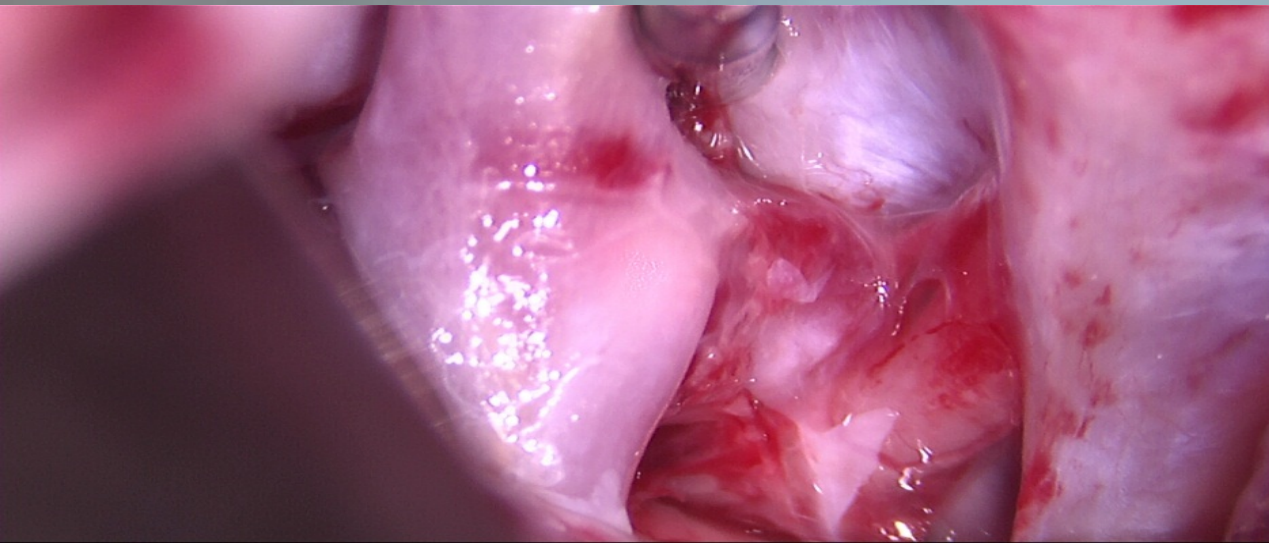
# Post-Clipping Angiogram

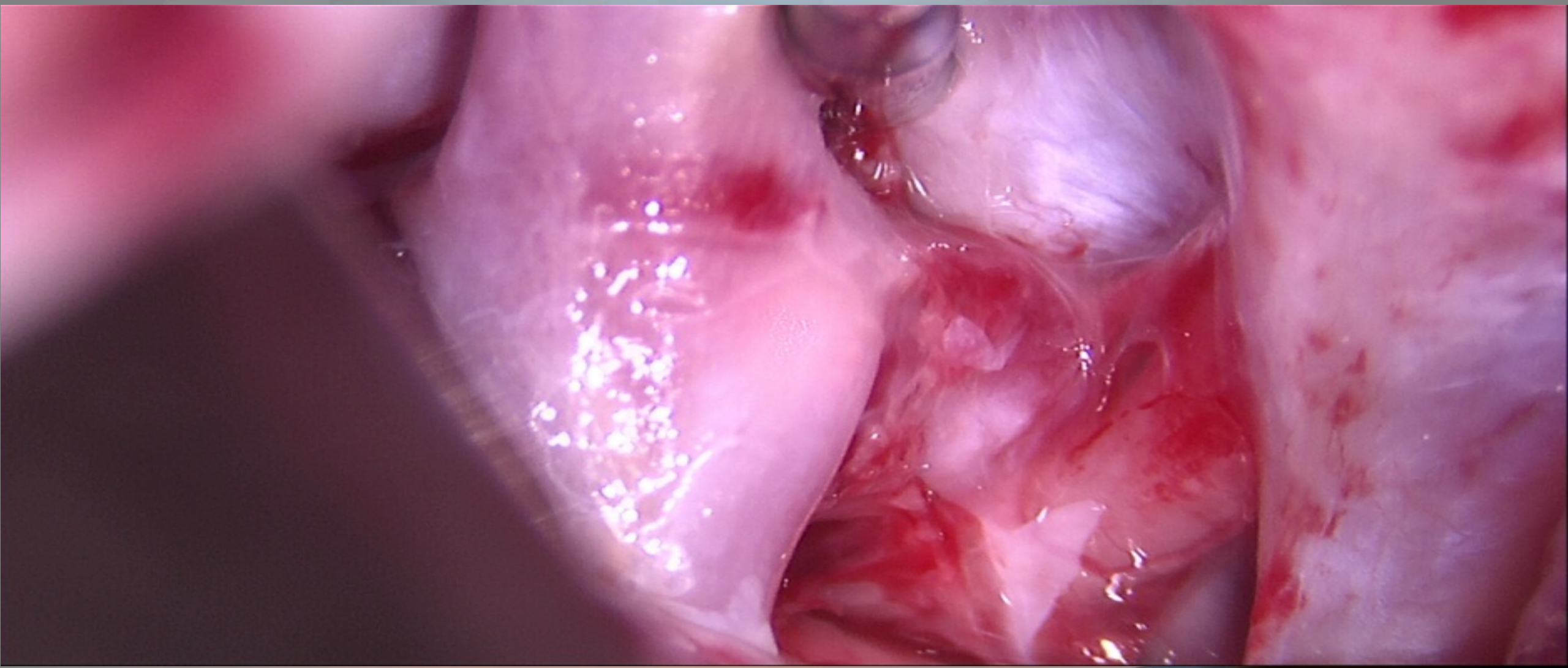


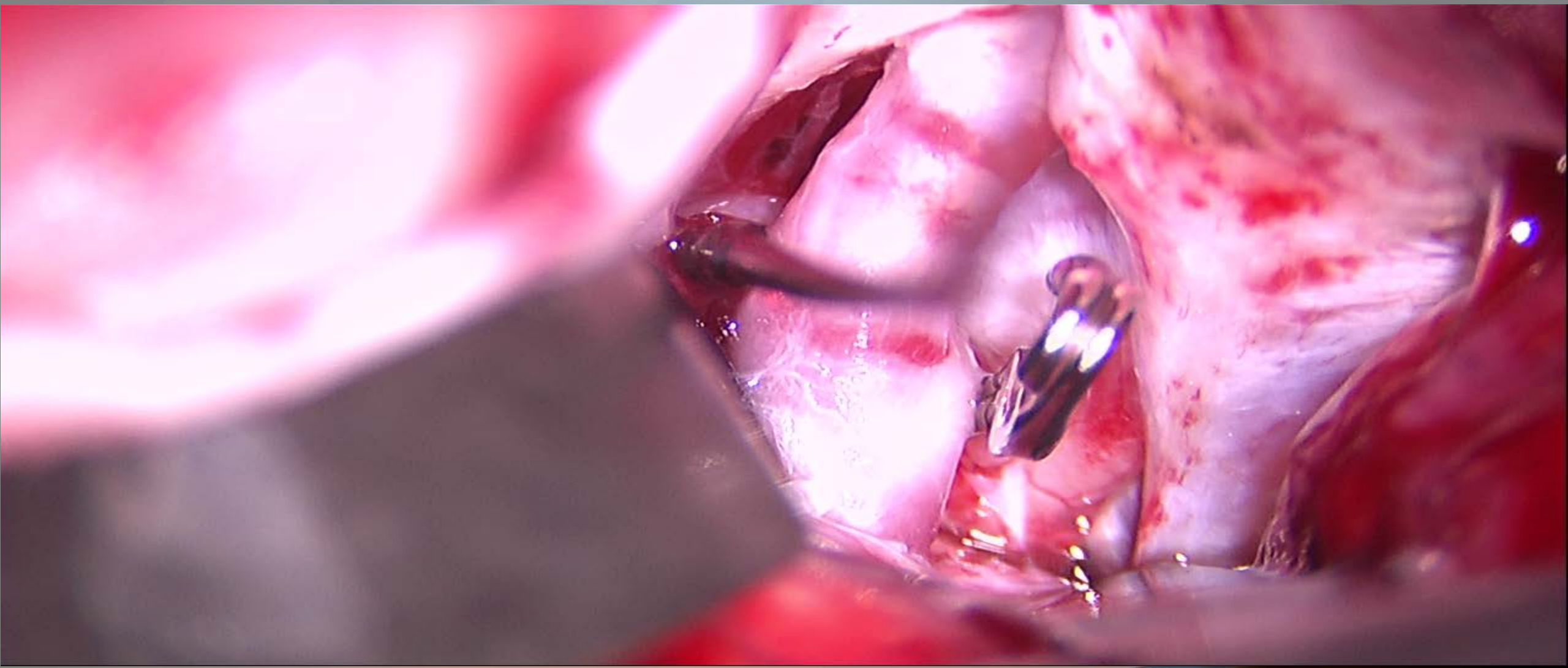
# Post-Clipping 3D Angiogram



# Clipping of PCOM aneurysm



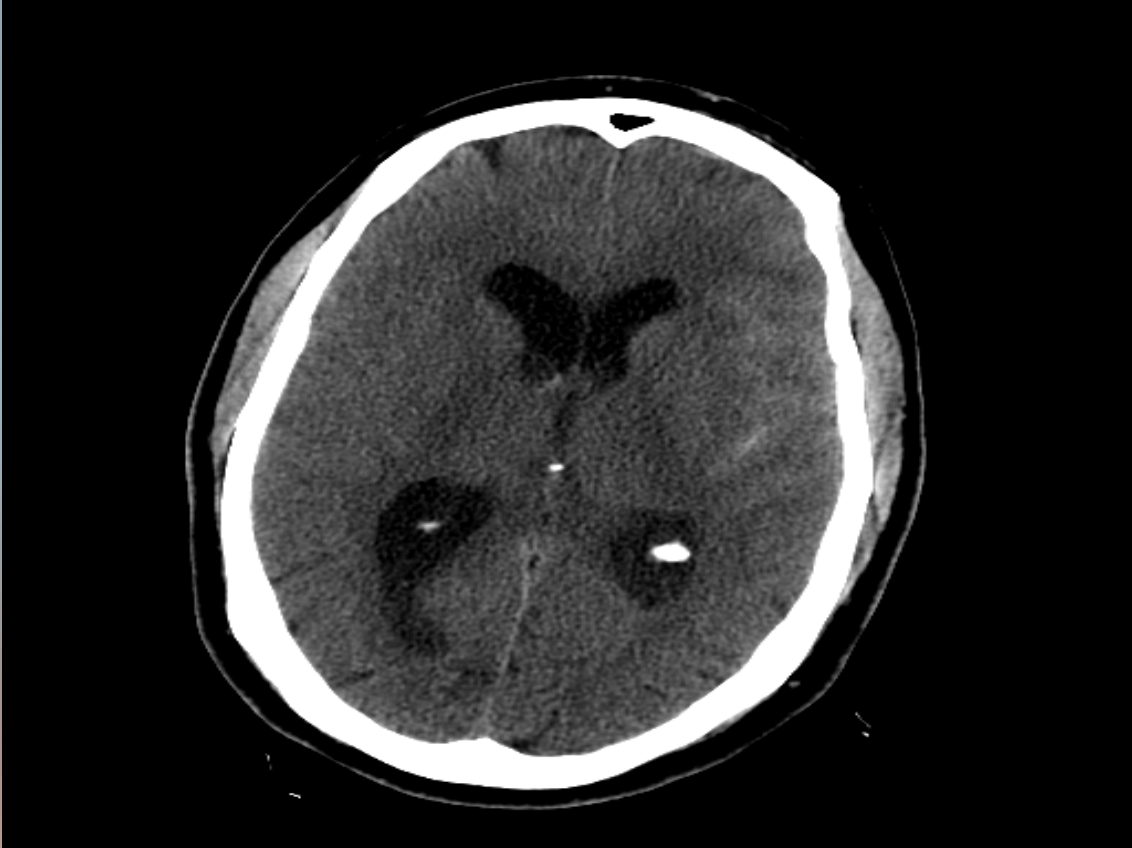
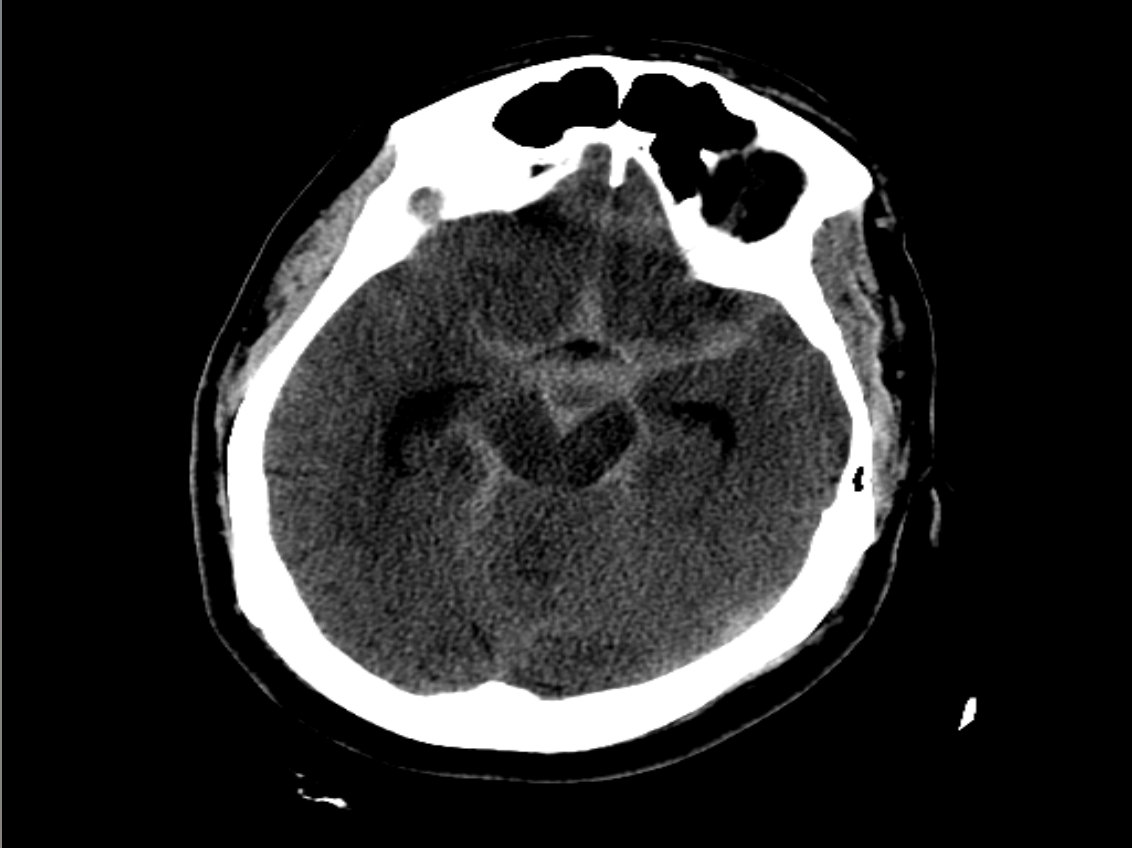



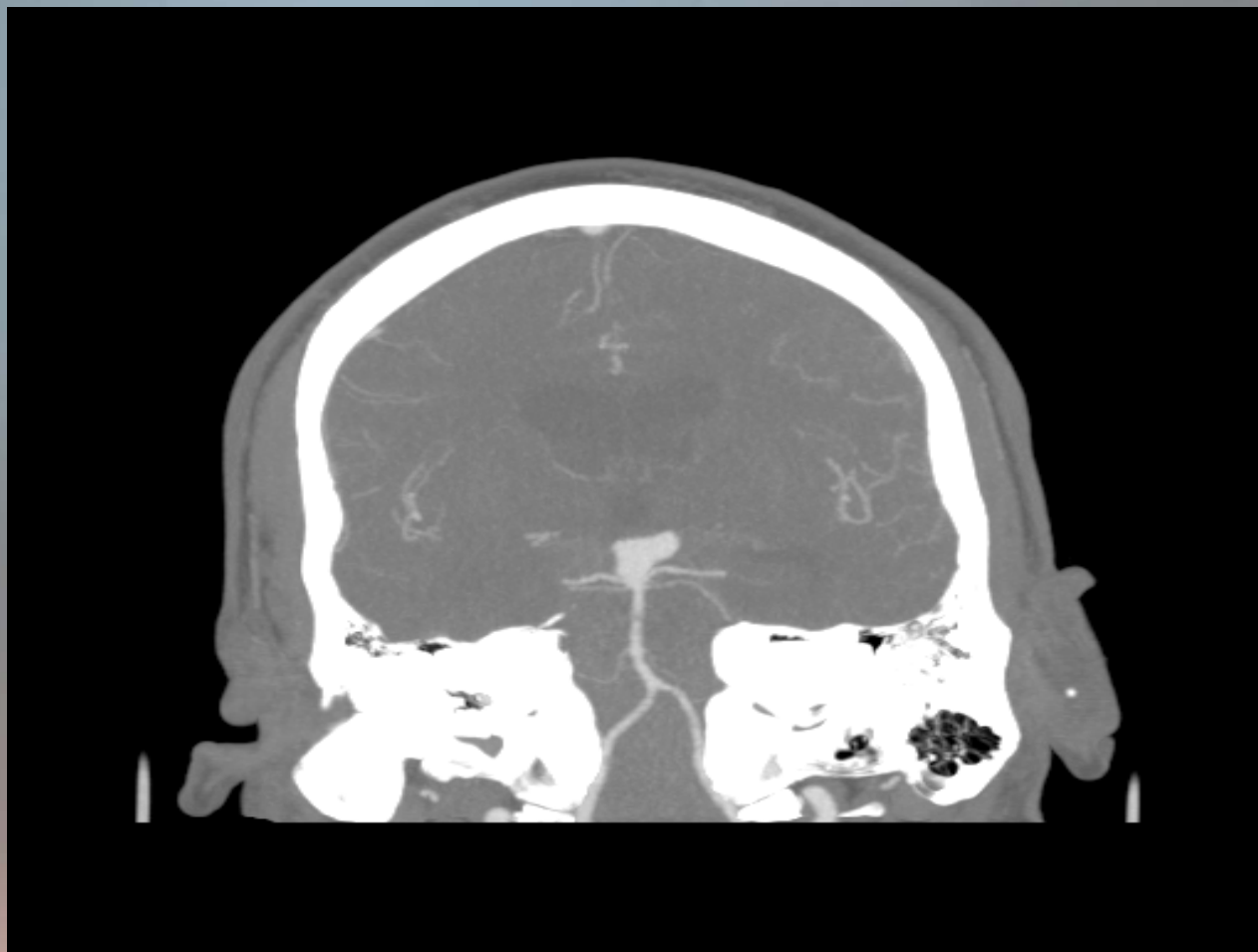## Case #2

- 57 year old male
- Fell down and passed out at work
  - Then complained of severe headache
- Past Medical History
  - Hypertension

# CT Scan

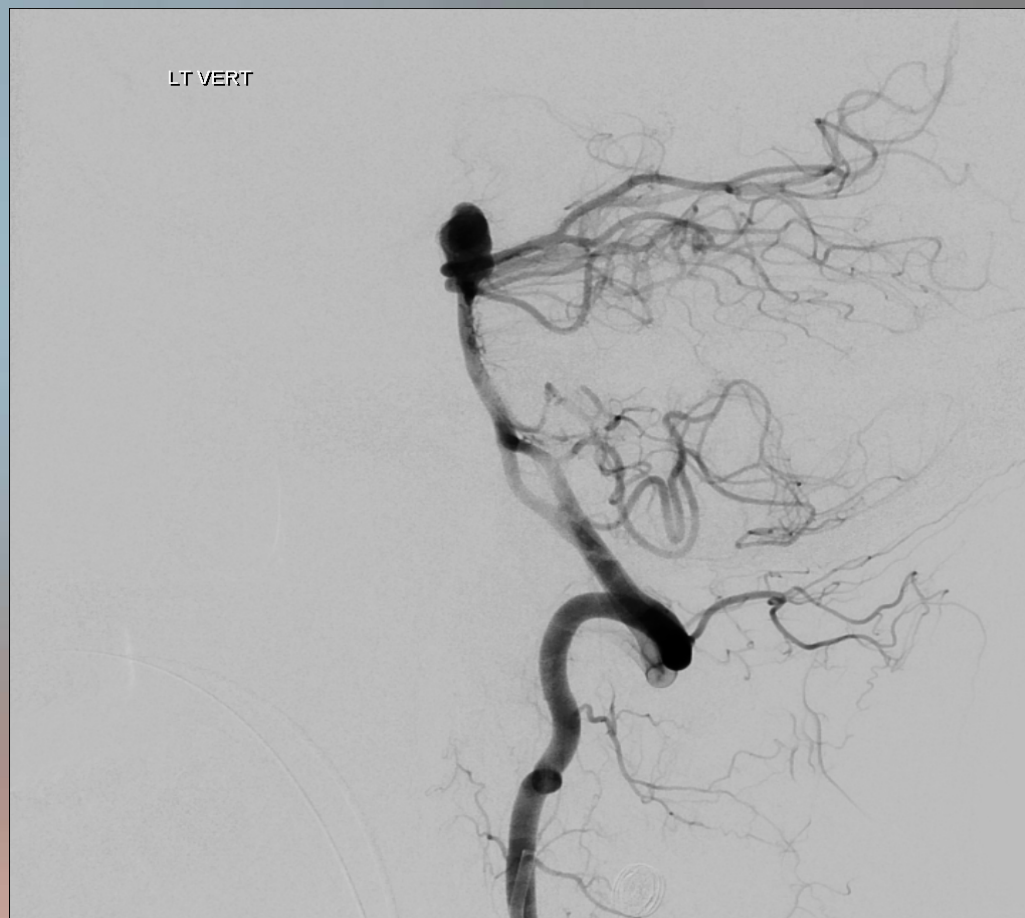
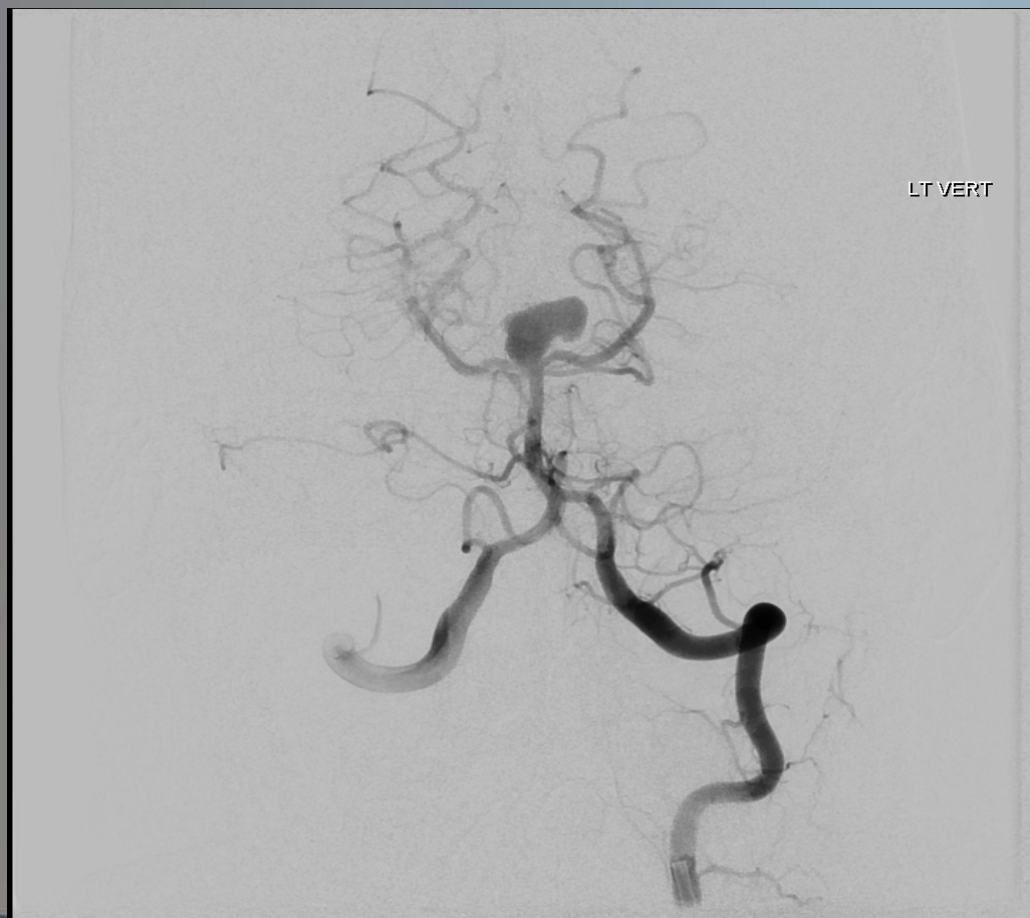

CTA

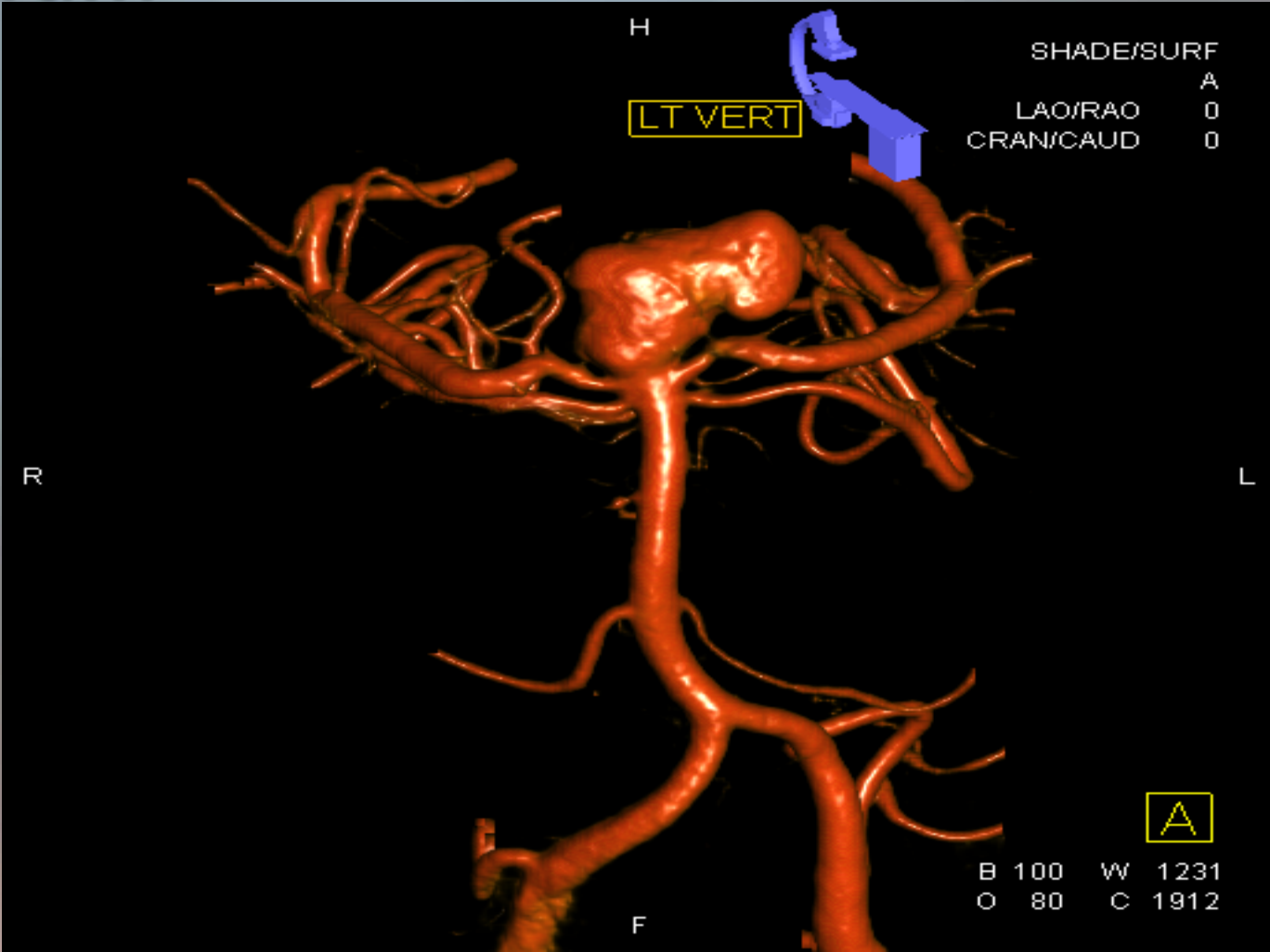




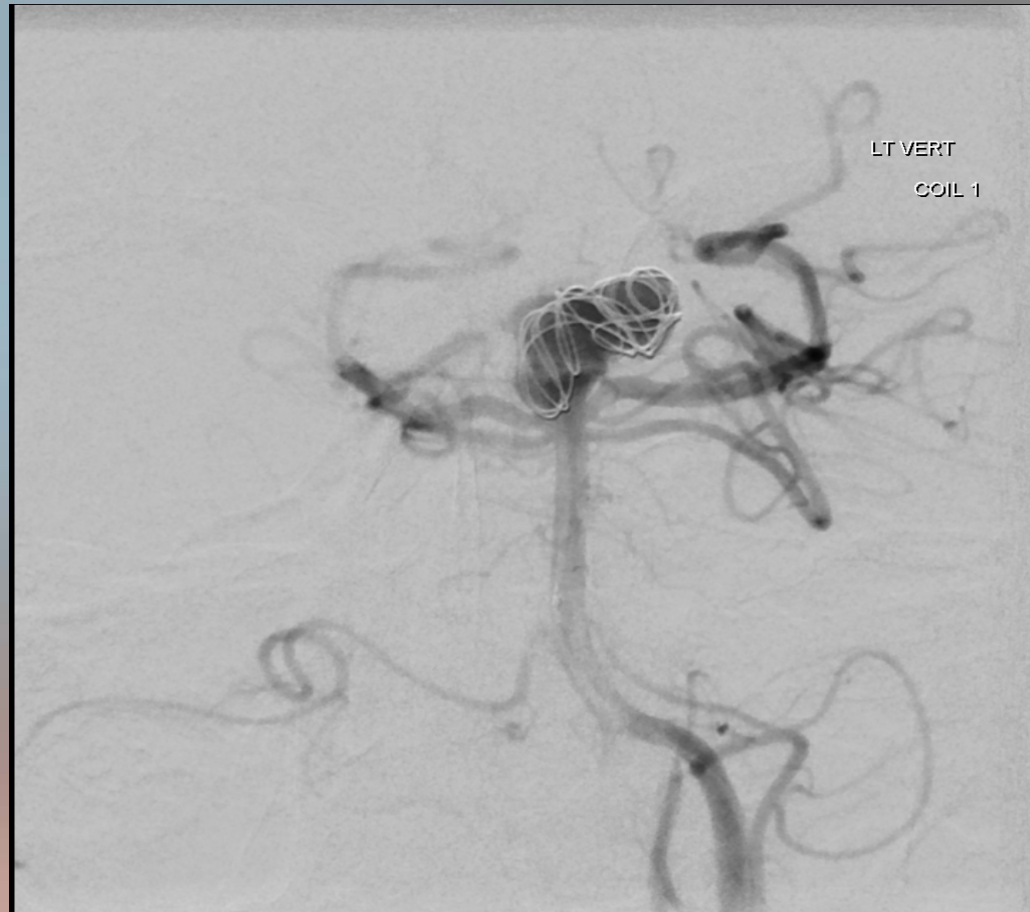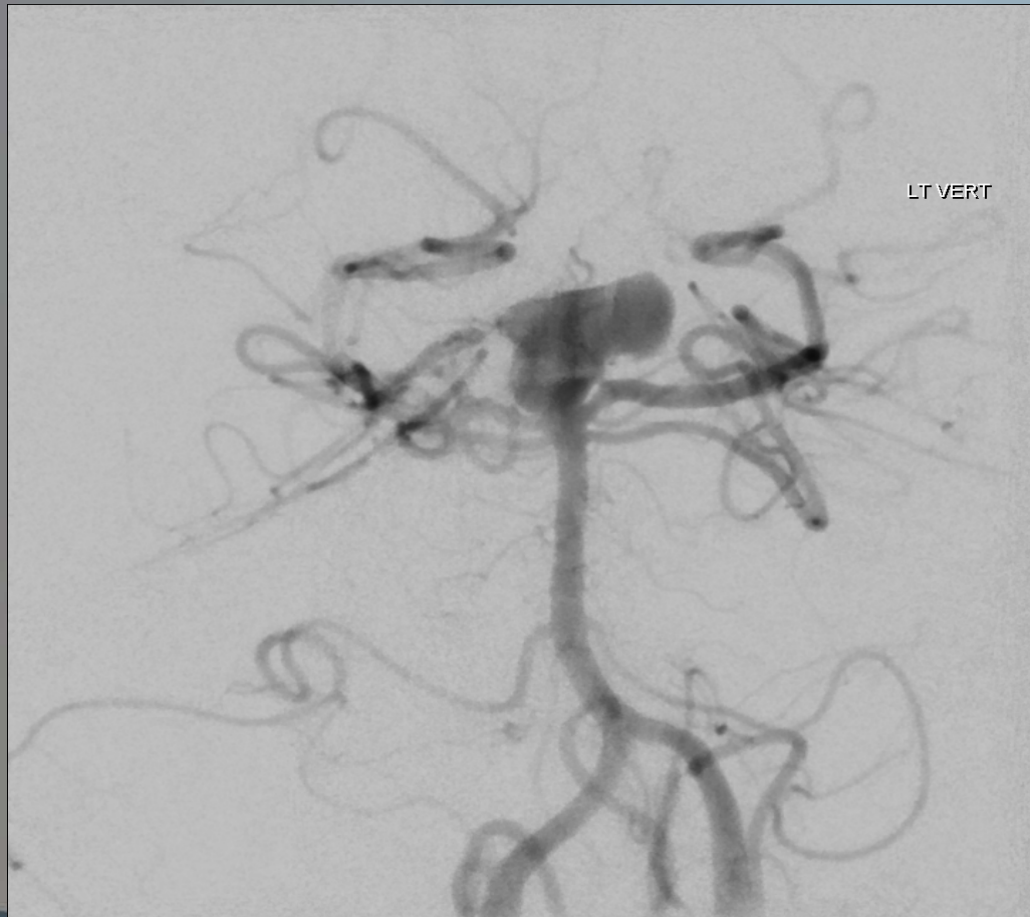# Angiogram



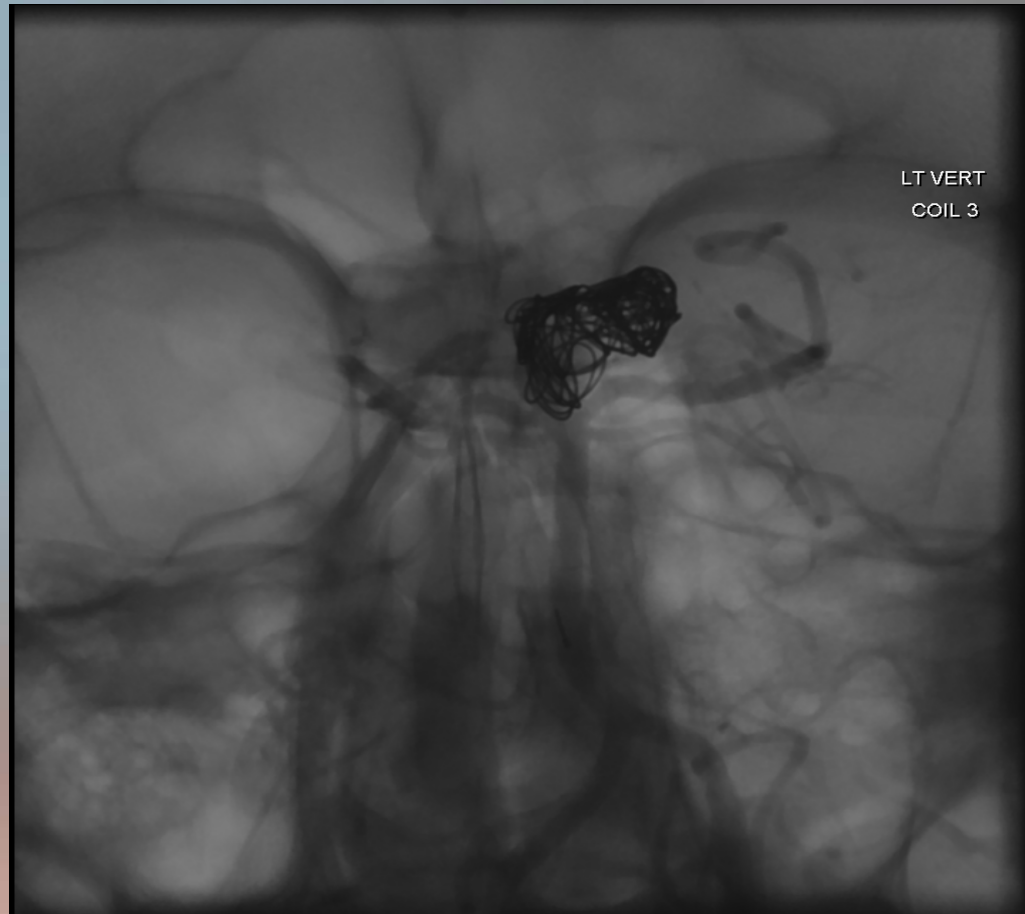
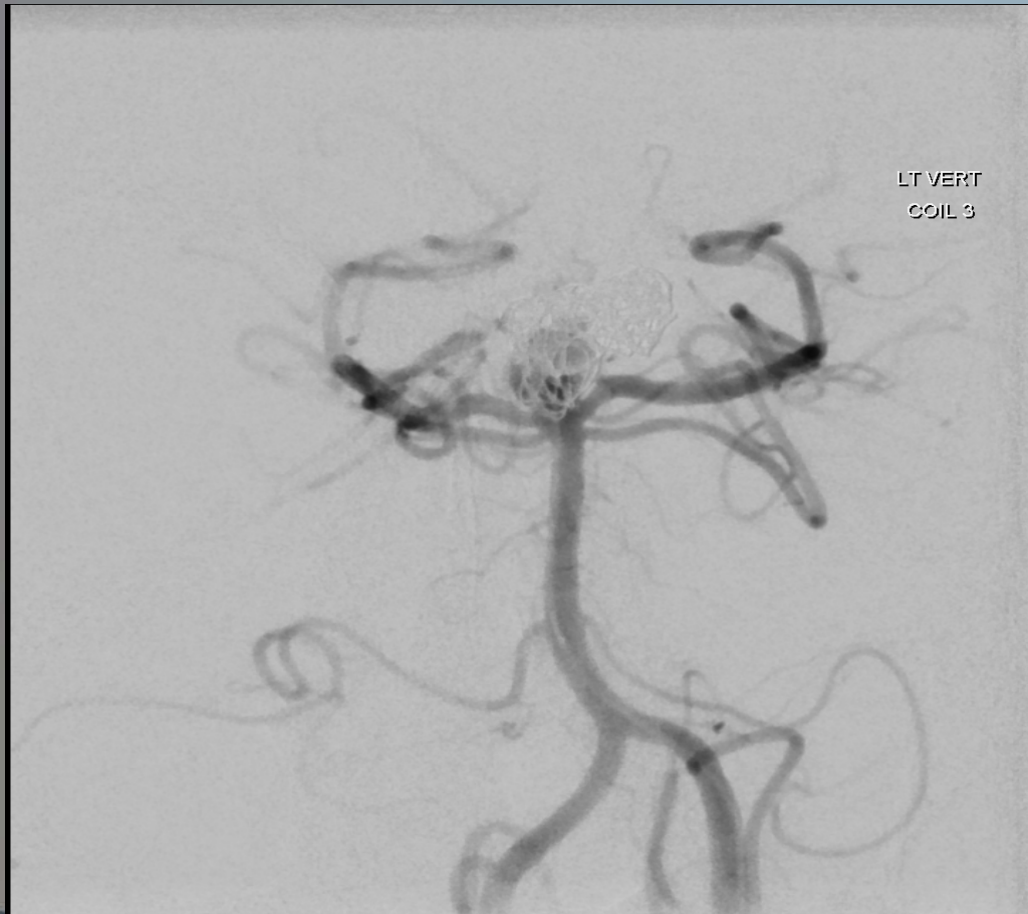# 3D Angiogram



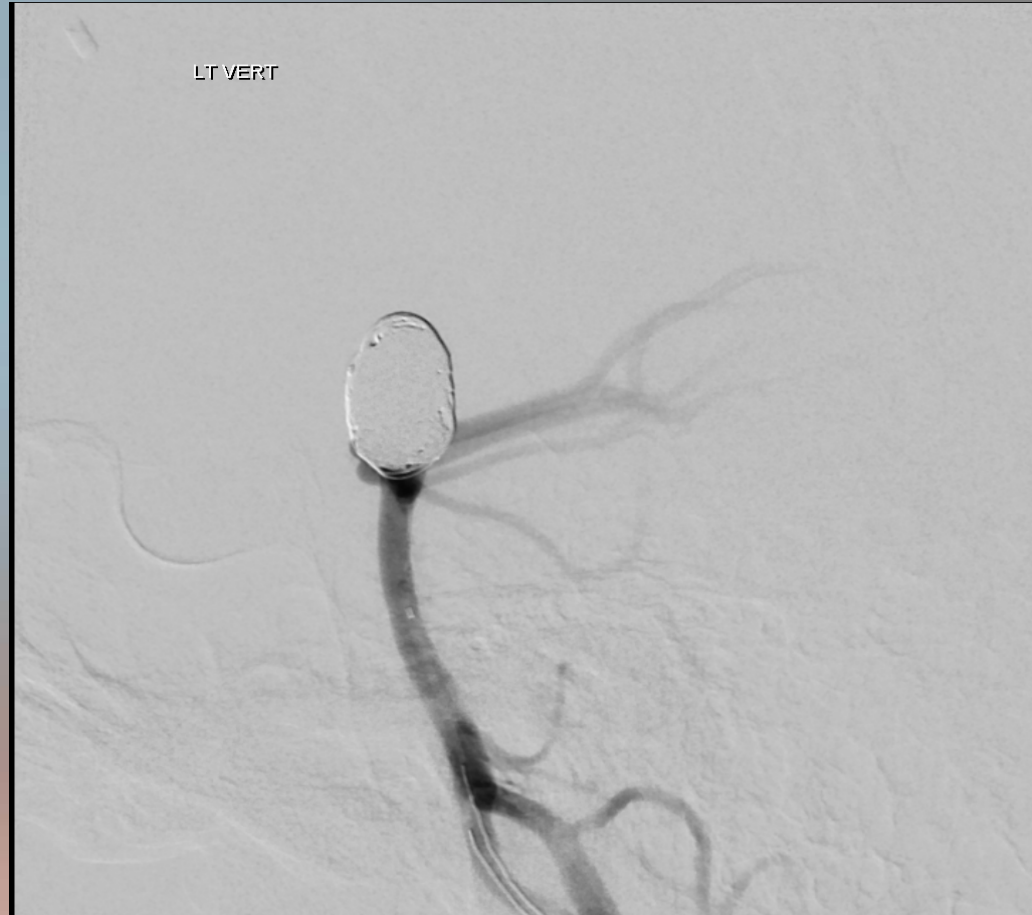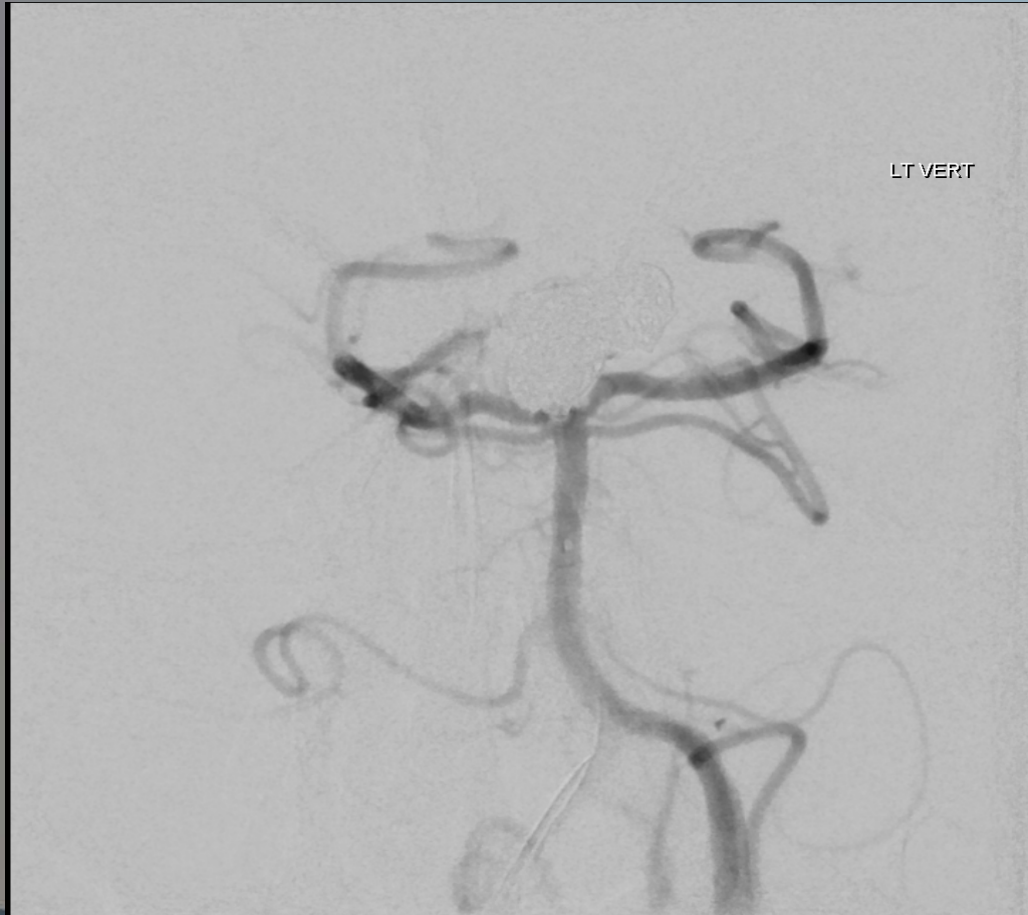# Coiling



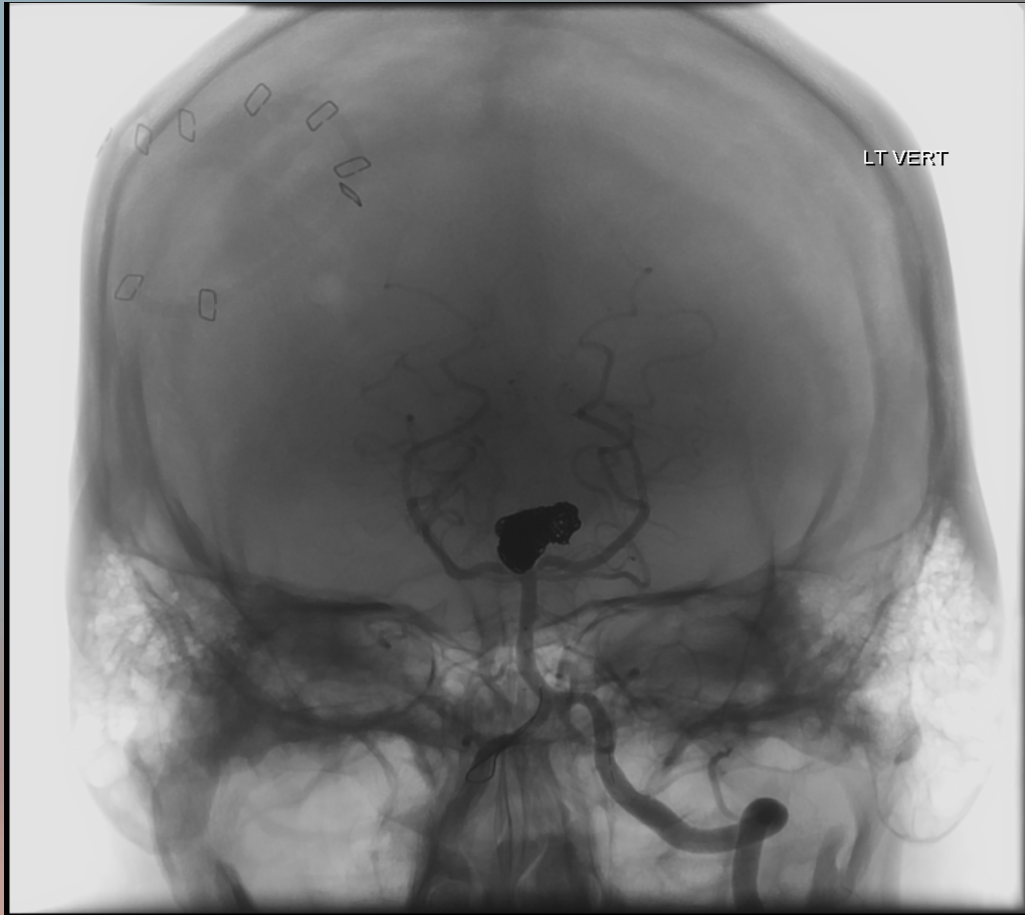
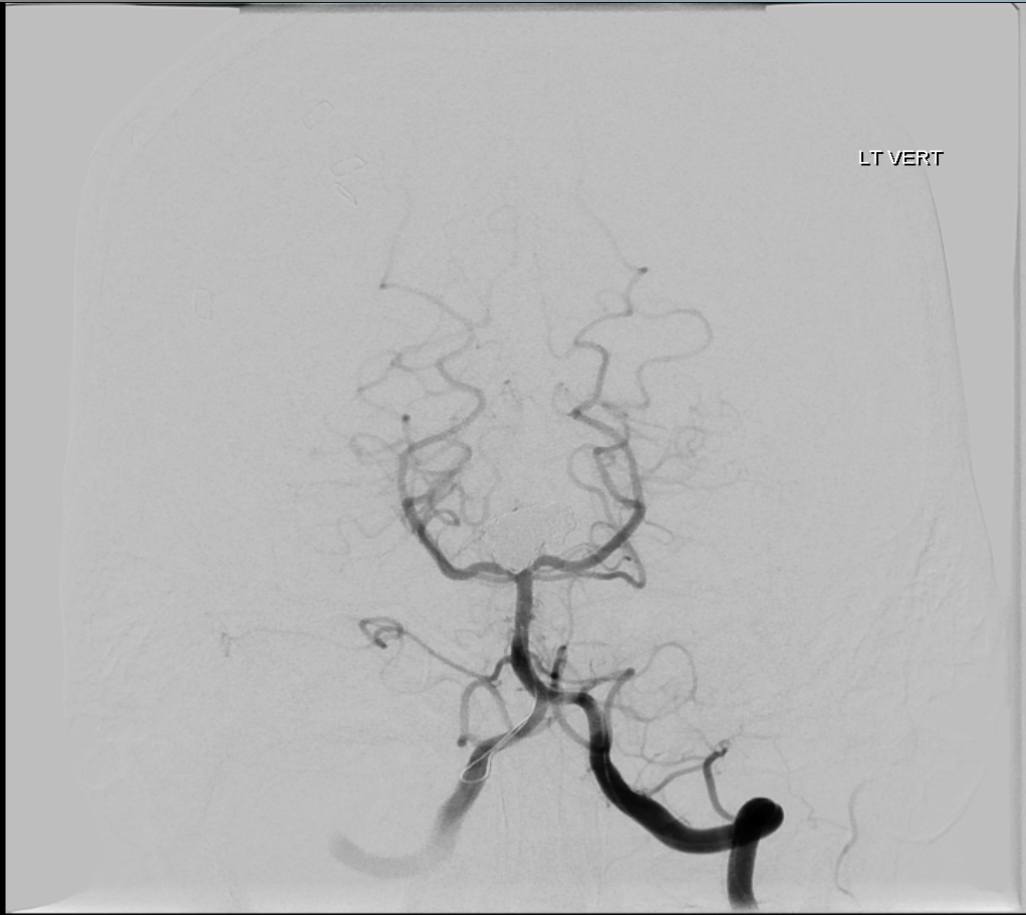# Coiling



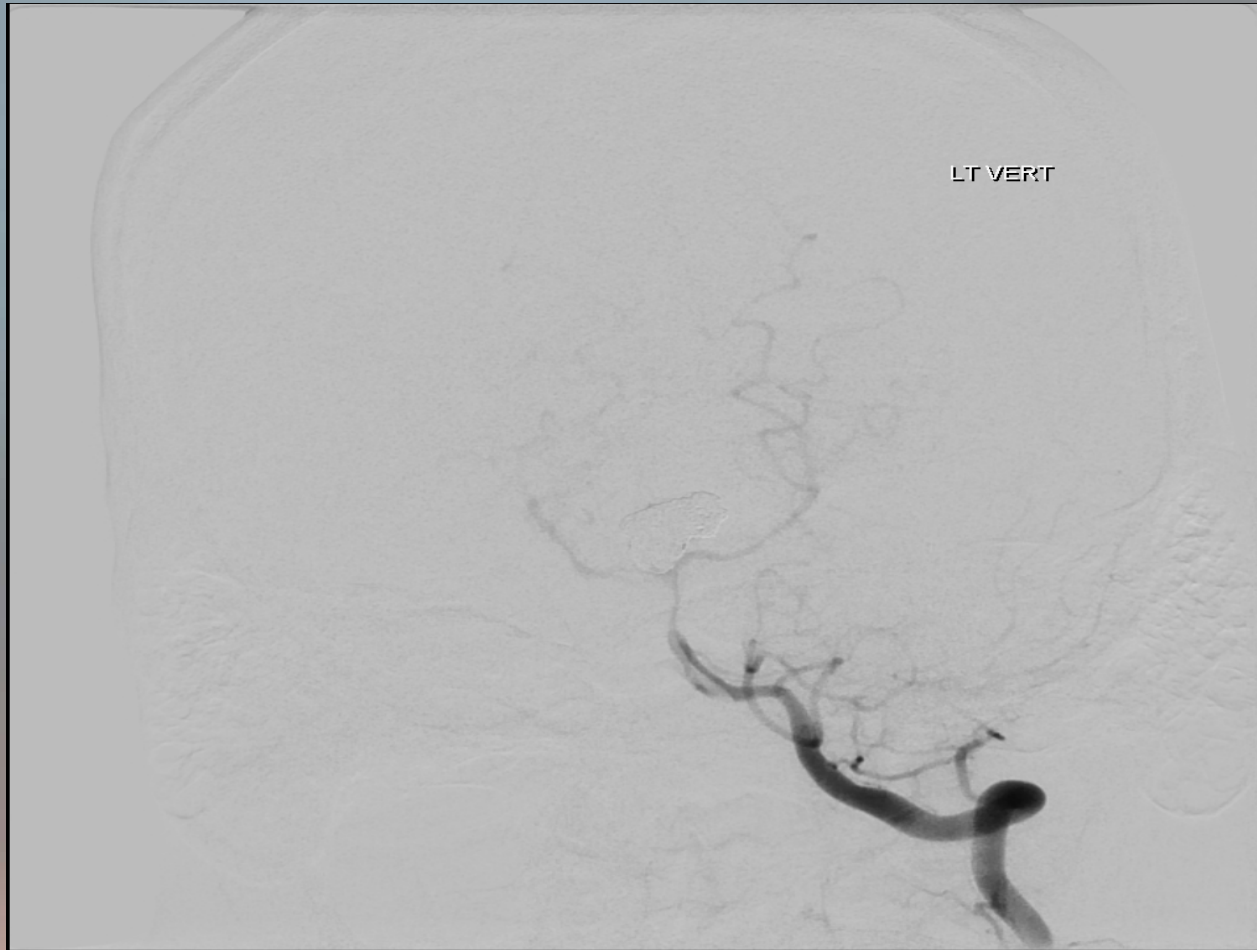# Completion of Coiling



# Final Image



# Vasospasm

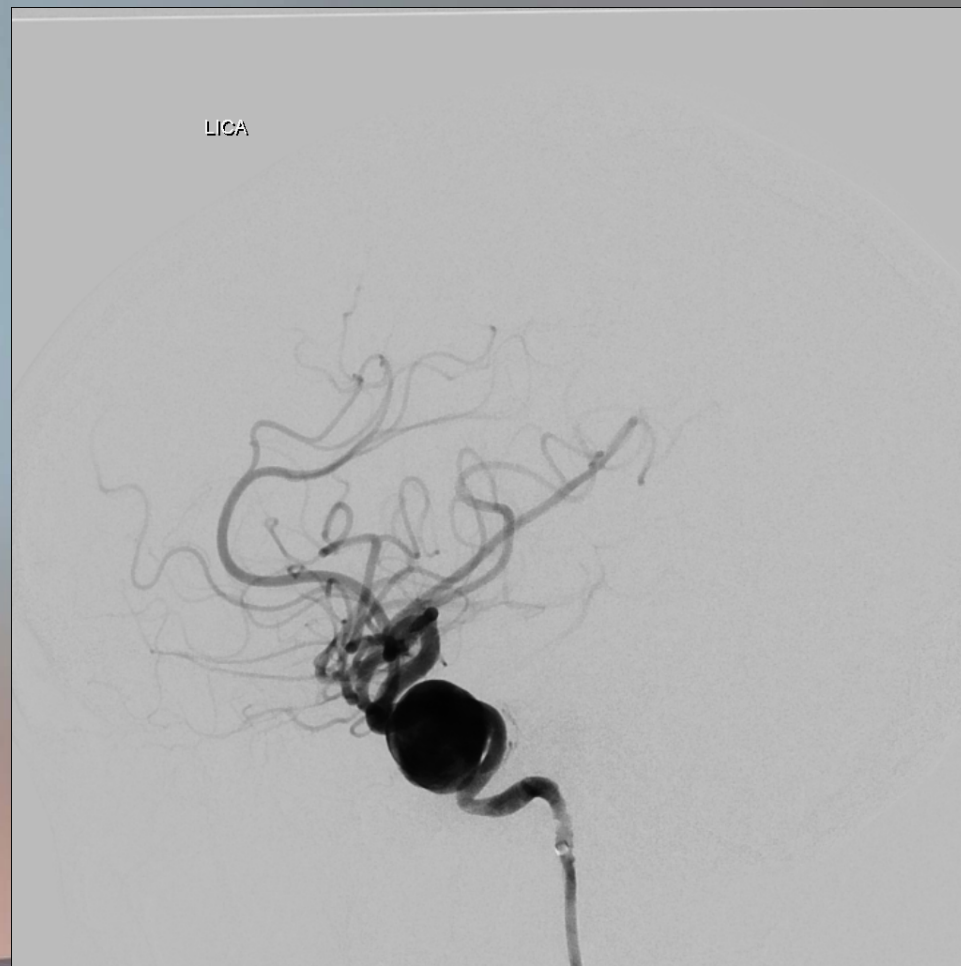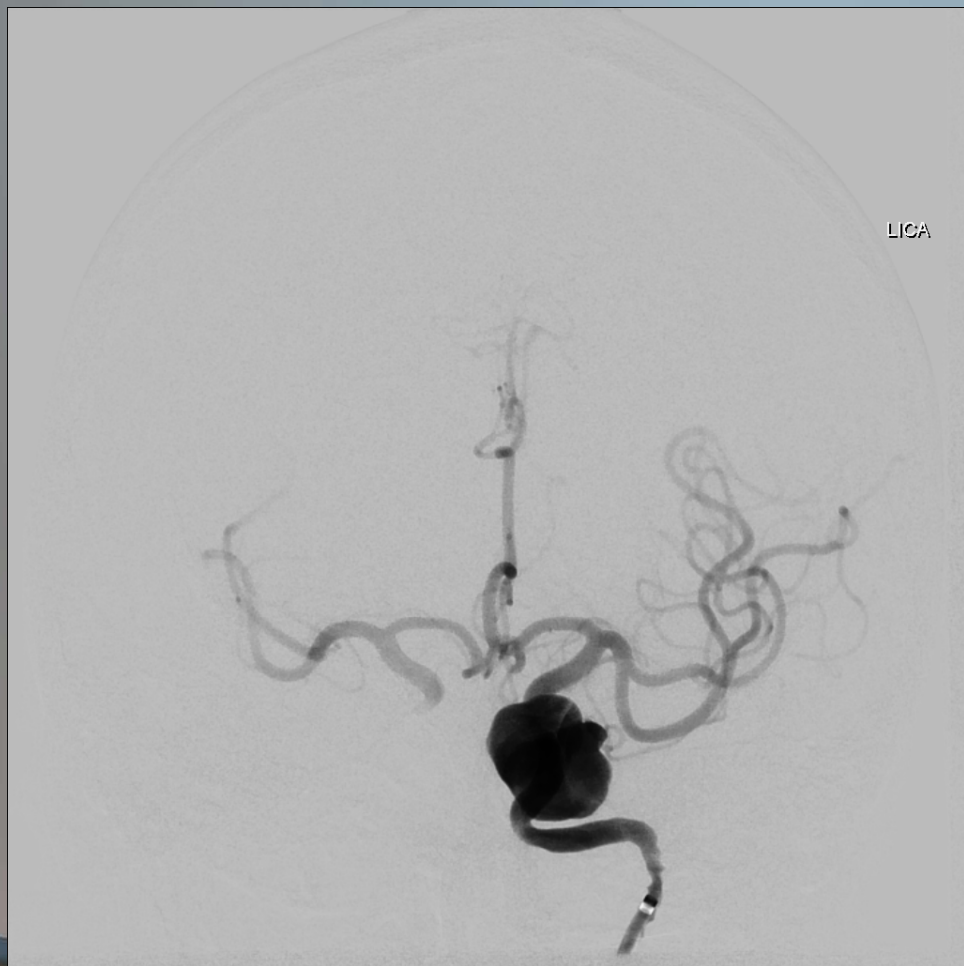


## Case #3

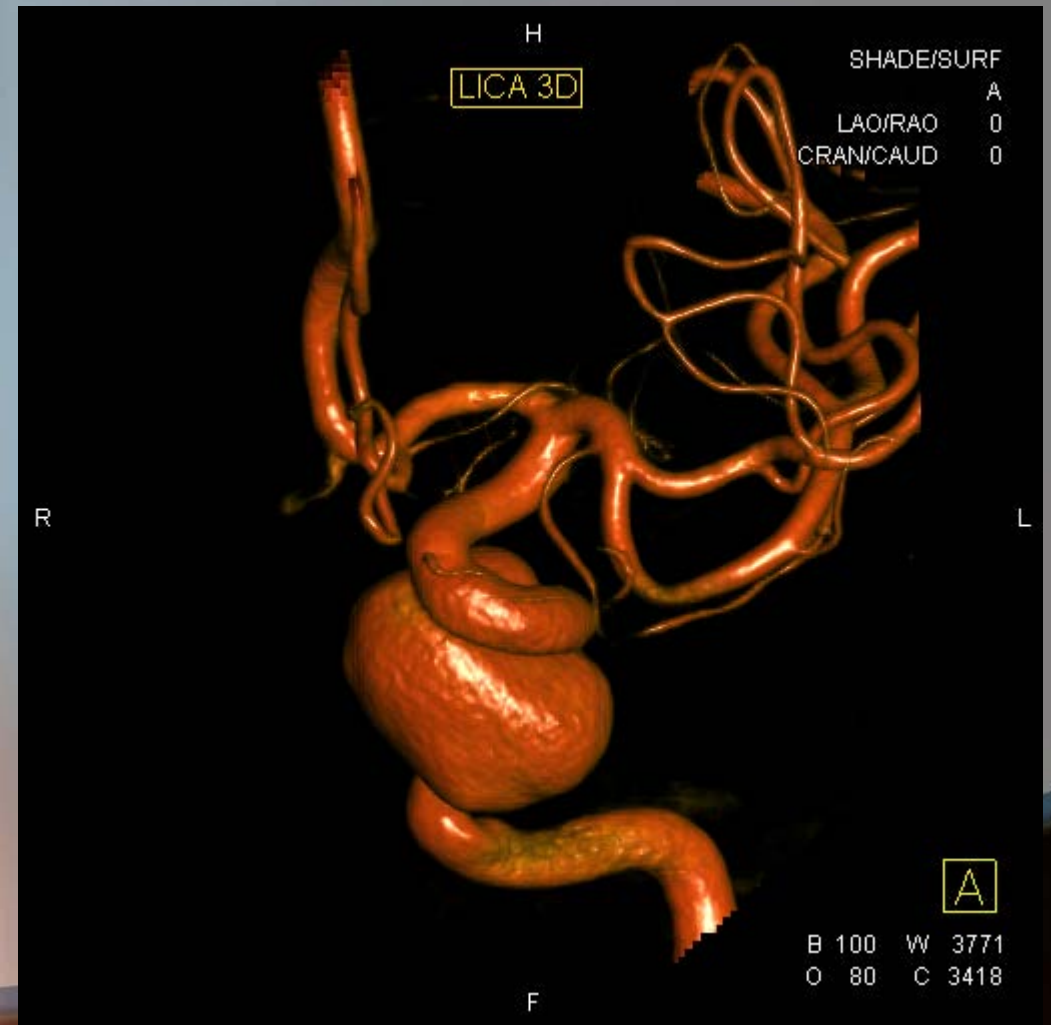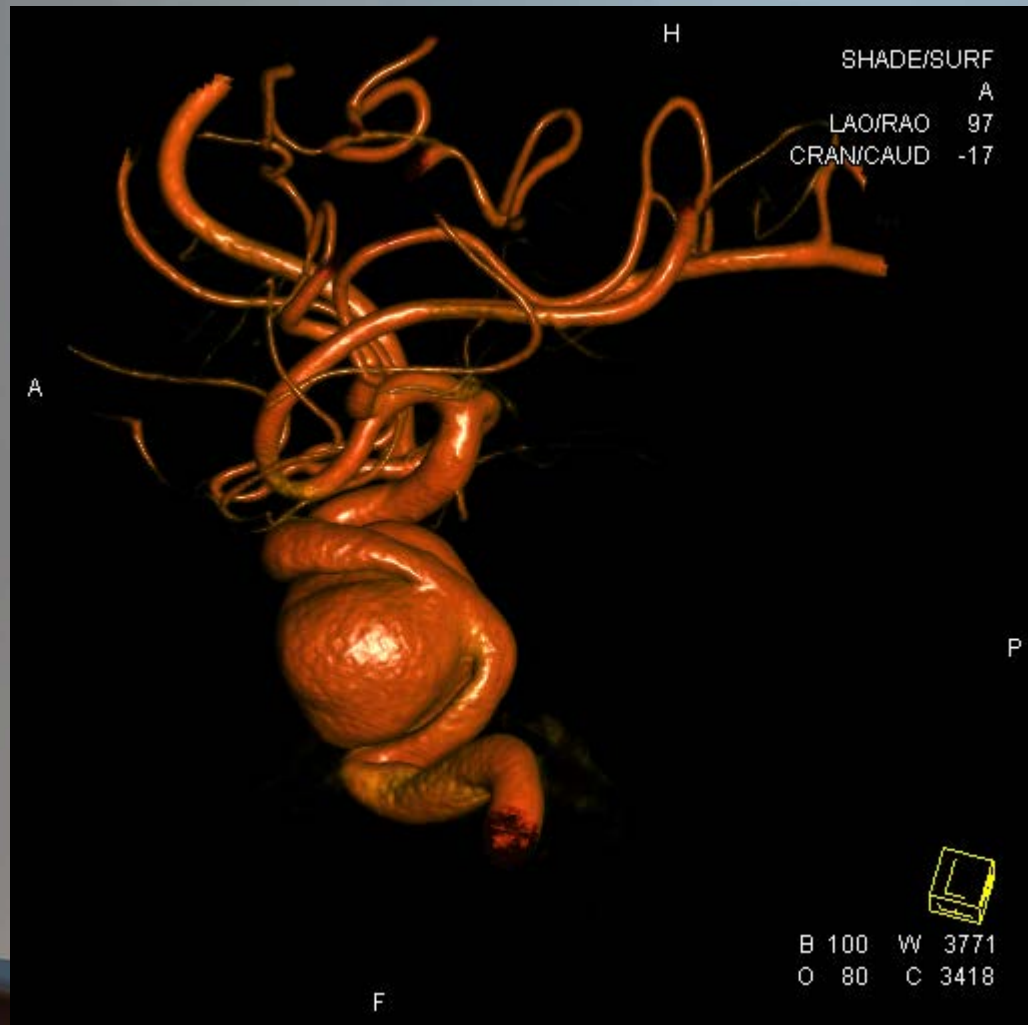- 69 year old female
- Several month history of double vision
  - Left 6<sup>th</sup> nerve palsy on exam
- Past Medical History
  - Hypertension
  - Smoking



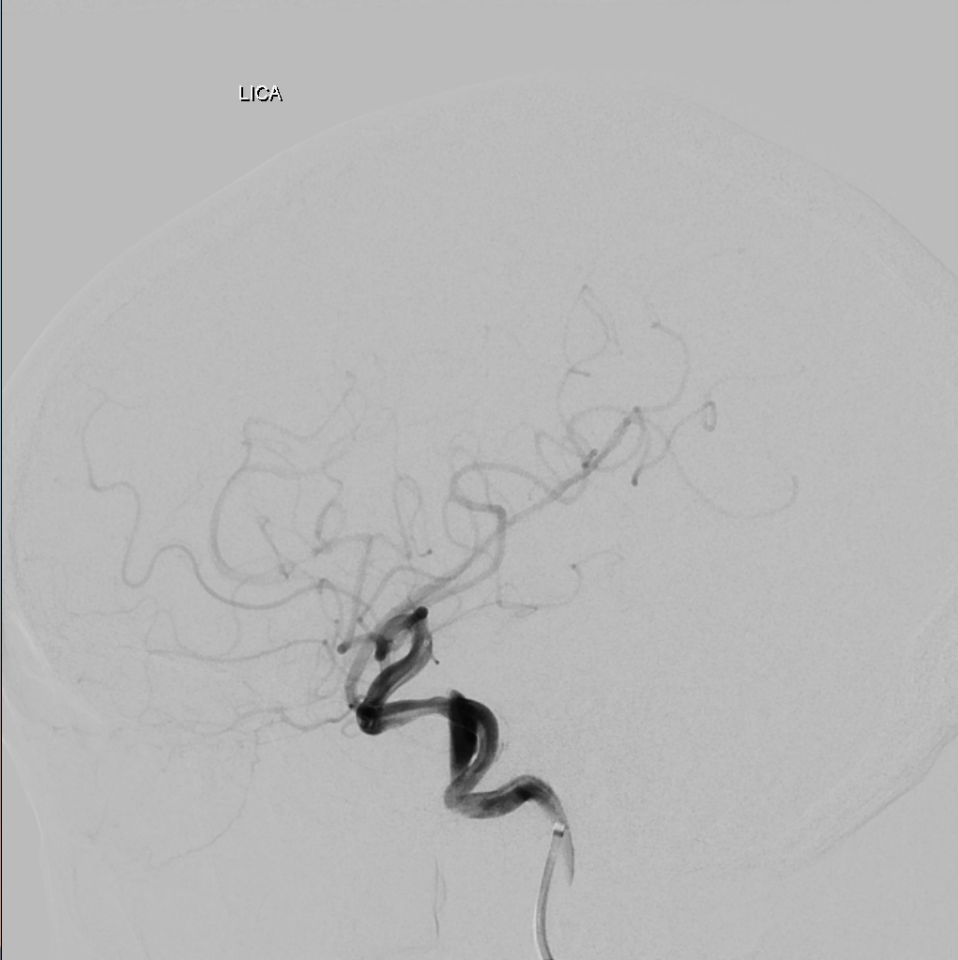
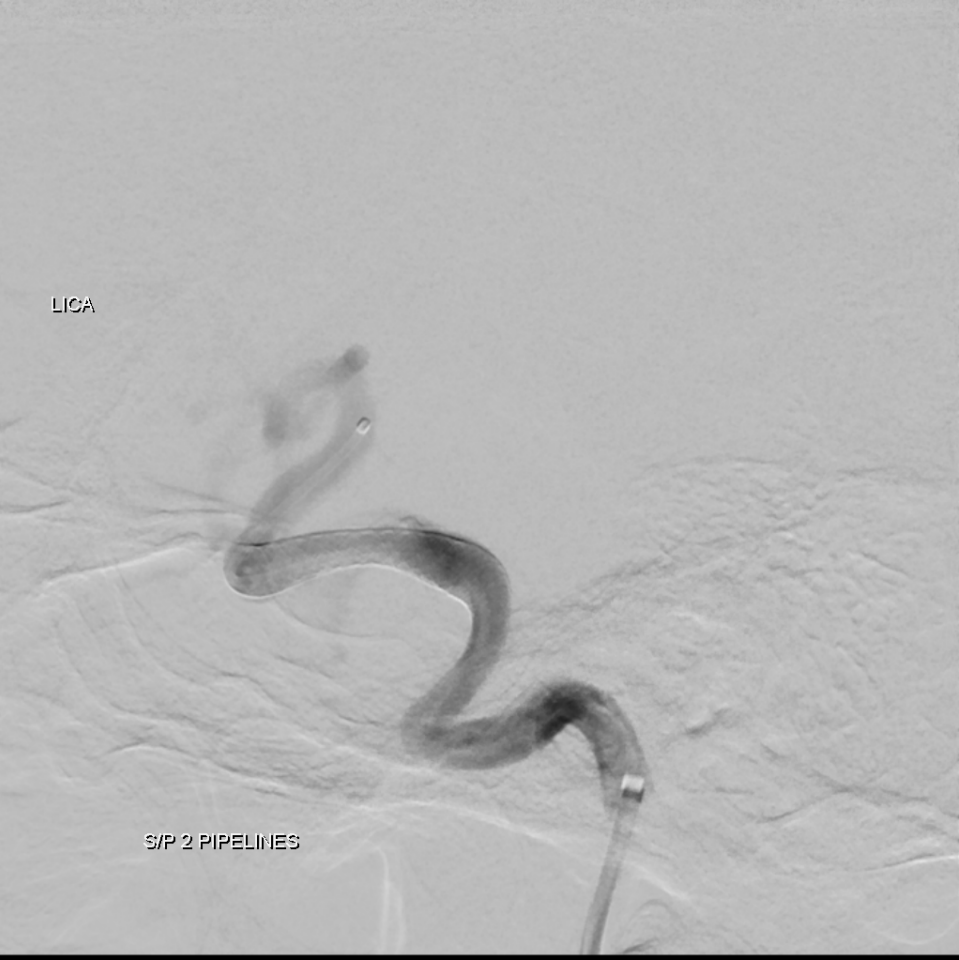# Angiogram



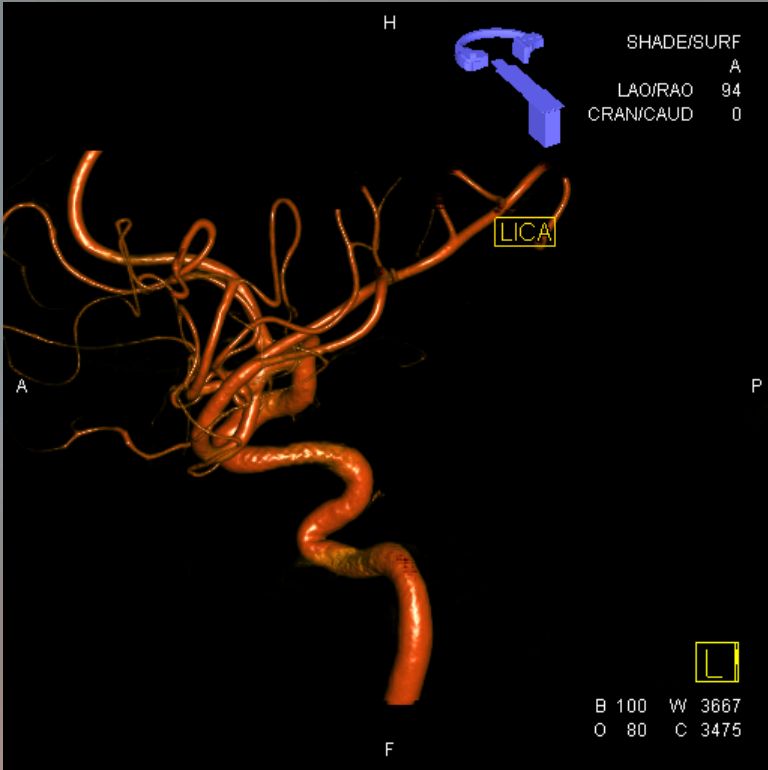
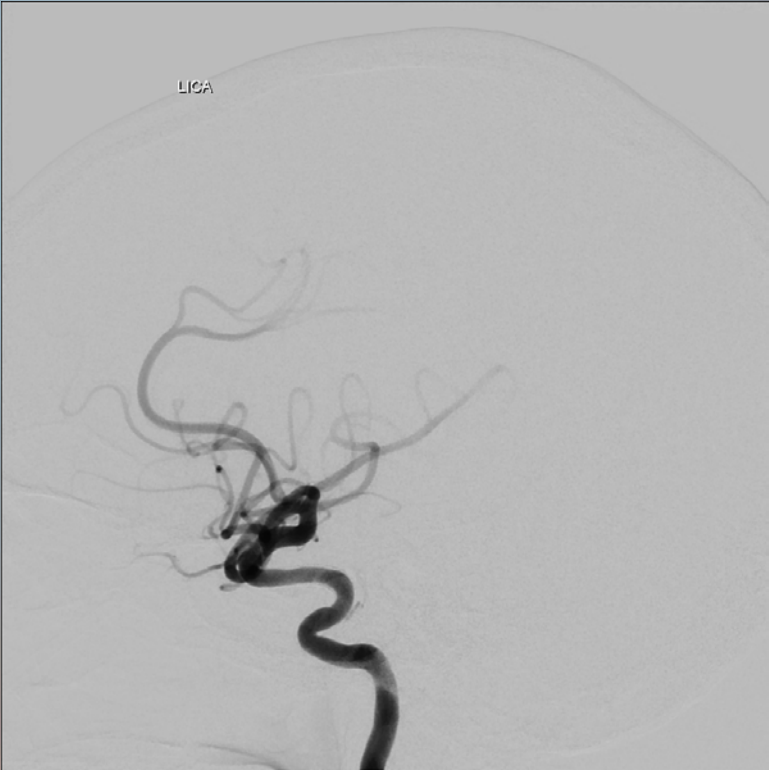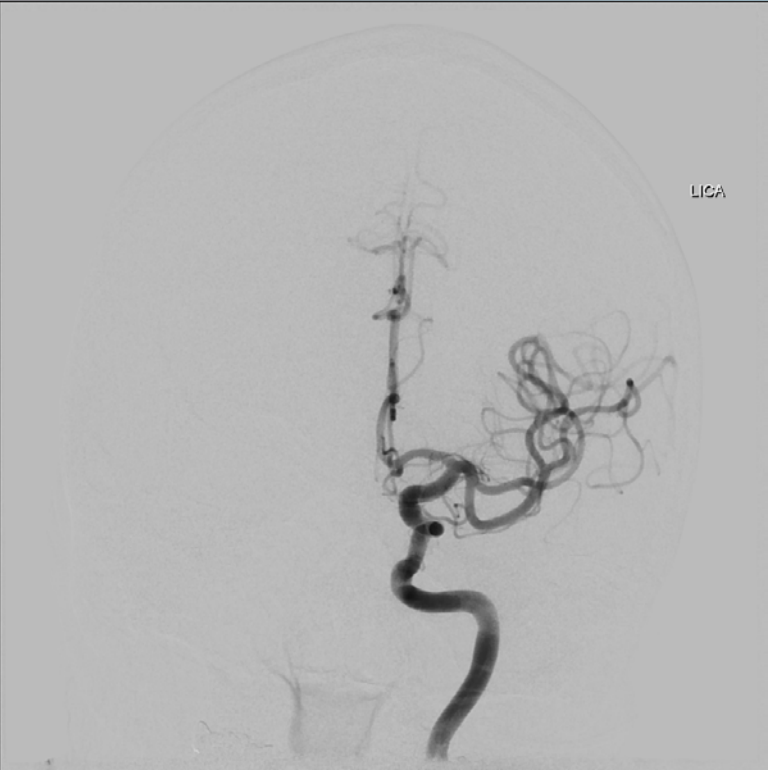# 3D Angiogram



# Flow-Diverting Stent Placement



# Six Month Follow-up Angiogram



<http://youtu.be/QR7sKMYCqec>

# Coiling Versus Clipping of Intracranial Aneurysms

Prasad Reddy, MD